

See discussions, stats, and author profiles for this publication at:  
<https://www.researchgate.net/publication/6988946>

# The Pathomechanics of Plantar Fasciitis

Article in *Sports Medicine* · February 2006

DOI: 10.2165/00007256-200636070-00004 · Source: PubMed

CITATIONS

114

READS

3,070

5 authors, including:



**James Smeathers**

Queensland University of Technol...

94 PUBLICATIONS 1,167 CITATIONS

SEE PROFILE



**Andrew P Hills**

University of Tasmania, Launcest...

299 PUBLICATIONS 6,679 CITATIONS

SEE PROFILE

Some of the authors of this publication are also working on these related projects:



Prevention of Falls - Balance Improvement in the Elderly and Parkinson Patients

[View project](#)

All content following this page was uploaded by [Andrew P Hills](#) on 25 May 2017.

The user has requested enhancement of the downloaded file.

# The Pathomechanics of Plantar Fasciitis

*Scott C. Wearing,<sup>1</sup> James E. Smeathers,<sup>1</sup> Stephen R. Urry,<sup>1</sup> Ewald M. Hennig<sup>2</sup> and Andrew P. Hills<sup>1</sup>*

- 1 Institute of Health and Biomedical Innovation, Queensland University of Technology, Kelvin Grove, Queensland, Australia  
2 Biomechanik Labor, University Duisburg-Essen, Essen, Germany

## Contents

Abstract .....	585
1. Anatomy of the Plantar Fascia .....	586
1.1 Gross Anatomy of the Plantar Fascia .....	586
1.2 Histological Anatomy of the Plantar Fascia .....	589
1.2.1 Neuroanatomy .....	590
1.2.2 Microcirculation .....	590
1.2.3 The Entthesis .....	590
2. Mechanical Properties of the Plantar Fascia .....	592
2.1 Structural Properties .....	593
2.2 Material Properties .....	593
3. Mechanical Function of the Plantar Fascia .....	594
3.1 Quasistatic Models of Plantar Fascial Function .....	594
3.2 Dynamic Function of the Medial Longitudinal Arch During Gait .....	597
3.3 Fascial Loading During Gait .....	598
4. Histopathology of Plantar Fasciitis .....	599
5. Aetiological Factors in Plantar Fasciitis .....	601
5.1 Ground Reaction Force in Plantar Fasciitis .....	602
5.2 Arch Mechanics in Plantar Fasciitis .....	603
6. Conclusions .....	603

## Abstract

Plantar fasciitis is a musculoskeletal disorder primarily affecting the fascial entheses. Although poorly understood, the development of plantar fasciitis is thought to have a mechanical origin. In particular, pes planus foot types and lower-limb biomechanics that result in a lowered medial longitudinal arch are thought to create excessive tensile strain within the fascia, producing microscopic tears and chronic inflammation. However, contrary to clinical doctrine, histological evidence does not support this concept, with inflammation rarely observed in chronic plantar fasciitis. Similarly, scientific support for the role of arch mechanics in the development of plantar fasciitis is equivocal, despite an abundance of

anecdotal evidence indicating a causal link between arch function and heel pain. This may, in part, reflect the difficulty in measuring arch mechanics *in vivo*. However, it may also indicate that tensile failure is not a predominant feature in the pathomechanics of plantar fasciitis. Alternative mechanisms including 'stress-shielding', vascular and metabolic disturbances, the formation of free radicals, hyperthermia and genetic factors have also been linked to degenerative change in connective tissues. Further research is needed to ascertain the importance of such factors in the development of plantar fasciitis.

Plantar fasciitis is a common musculoskeletal disorder characterised by pain involving the inferomedial aspect of the heel that is exacerbated following periods of non-weightbearing.<sup>[1]</sup> Synonymous with terms such as painful heel syndrome, heel spur syndrome and runner's heel, plantar fasciitis has been reported to affect between 10% and 20% of injured athletes.<sup>[2-4]</sup> The clinical course of plantar fasciitis is unknown.<sup>[5]</sup> Although 5–10% of patients progress to surgery,<sup>[6]</sup> the majority of cases ostensibly resolve within 6–18 months of conservative therapy,<sup>[7-9]</sup> leading some authors to suggest that plantar fasciitis represents a self-limiting condition.<sup>[5,10-12]</sup> While conservative therapy appears to be the mainstay of treatment, there is controversy regarding the most efficacious programme.<sup>[13]</sup> Although all treatments have reputedly provided some level of relief, the final outcome, as well as the financial and personal burden imposed by each treatment, varies markedly across protocols.<sup>[14,15]</sup>

While numerous local and systemic factors may produce inferior heel pain,<sup>[16-18]</sup> the diagnosis of plantar fasciitis is usually based on clinical criteria alone. Pain localised to the medial tubercle of the calcaneus is considered pathognomonic and is the most widely reported clinical sign.<sup>[19,20]</sup> Diagnostic ultrasonography, although infrequently used, typically demonstrates diffuse or localised hypoechoic areas within a thickened calcaneal attachment.<sup>[21]</sup> In contrast to inflammatory enthesitis, the development of plantar fasciitis is primarily thought to be

mechanical in origin;<sup>[22,23]</sup> however, little is known regarding the pathogenesis of the condition.

This article presents an overview of the anatomy and function of the plantar fascia and provides a critical review of the pathogenesis of plantar fasciitis. Given the lack of published information relating specifically to the histological appearance of the fascia and the histopathology of plantar fasciitis, the article briefly details the general histological appearance of connective tissue structures and, where pertinent, draws analogies to the histopathology of overuse injuries of tendon and ligament. Particular emphasis is placed on the function of the plantar fascia and the role of arch mechanics in the development of plantar fasciitis.

## 1. Anatomy of the Plantar Fascia

### 1.1 Gross Anatomy of the Plantar Fascia

The plantar fascia or plantar aponeurosis is the investing fascia of the sole of foot and forms a strong mechanical linkage between the calcaneus and the toes. Synonymous with the deep fascia,<sup>[24]</sup> the plantar aponeurosis arises predominantly from the medial process of the calcaneal tuberosity and attaches distally, through several slips, to the plantar aspect of the forefoot as well as the medial and lateral intermuscular septa.<sup>[25]</sup> Anatomically, the fascia can be divided into three components or bands: the medial, lateral and central (figure 1).<sup>[26,27]</sup> While the medial band is frequently implicated in

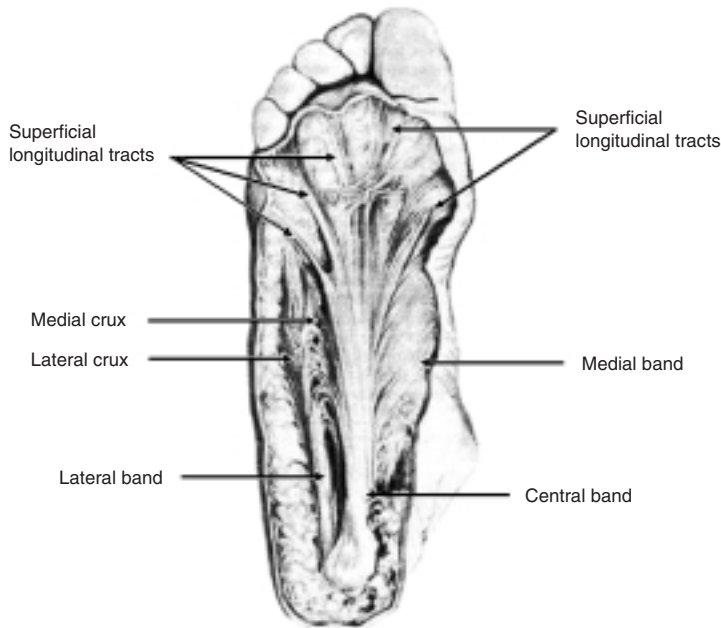


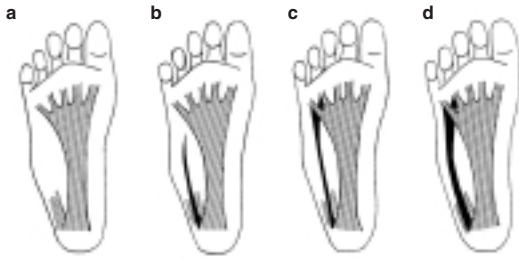
Fig. 1. The three bands or components of the plantar fascia (reproduced from Sarrafian,<sup>[25]</sup> with permission).

the development of plantar fasciitis,<sup>[28]</sup> anatomical observations have revealed this structure to be thin and virtually non-existent at its proximal level.<sup>[25]</sup> Similarly, the structure of the lateral band appears variable in nature,<sup>[29,30]</sup> ranging from relatively thick and fully developed, to complete absence in approximately 12% of individuals (figure 2).<sup>[31]</sup> When present, the lateral band arises from the lateral margin of the medial tubercle and provides a partial origin for the abductor digiti minimi muscle.<sup>[24]</sup> At the level of the cuboid, the lateral band bifurcates into medial and lateral crura. The stronger lateral crux inserts into the base of the fifth metatarsal to form the plantar ligament of the sole.<sup>[24,32]</sup> The medial crux, in contrast, courses distally and receives a contribution from the central band of the plantar fascia<sup>[29]</sup> before coursing deep and inserting into the plantar plate of either the third,<sup>[25]</sup> fourth<sup>[29]</sup> or fifth<sup>[30]</sup> metatarsophalangeal joint. While Cralley et al.<sup>[29]</sup> proposed that the medial crux may have signifi-

cant implications in the function of the plantar fascia, the importance of this structure is unknown.

The central aponeurotic band is often cited as the major component of the plantar fascia both structurally and functionally.<sup>[30,33]</sup> Triangular in shape, the apex originates from the plantar aspect of the medial process of the calcaneal tuberosity, where it serves as a partial origin for flexor digitorum brevis as it conforms to the convex plantar surface of the calcaneus.<sup>[24,27]</sup> Although often quoted as a continuation of either the triceps surae or plantaris tendon,<sup>[34,35]</sup> ontogenetic studies suggest that the origin of the central component develops independently in humans<sup>[31]</sup> and has been shown to be independent of the tendo-achilles in adults.<sup>[36]</sup>

Ranging from 12 to 29mm in width at its origin,<sup>[37,38]</sup> the central band diverges as it extends distally.<sup>[24]</sup> At the mid-metatarsal level, the aponeurosis separates into five longitudinally orientated bands.<sup>[39]</sup> Each band subsequently divides, proximal to the metatarsal heads, to form superficial and deep



**Fig. 2.** The anatomical variations of the lateral component of the plantar fascia. (a) completely absent; (b) thin and lacking a medial crux; (c) completely developed medial and lateral crux but thin; and (d) complete and well developed (reproduced from Sarrafian,<sup>[25]</sup> with permission).

tracts (figure 3).<sup>[40]</sup> While the two marginal superficial tracts course obliquely to the sides of the foot, the central three superficial tracts continue distally and reach: (i) between the first and second digits; (ii) the base of the third digit or the interspace between the third and fourth digits; and (iii) the base of the fifth digit or the interval between the fourth and fifth toes.<sup>[25,39]</sup> Anterior to the metatarsal heads, the central superficial tracts insert into the skin and contribute to the formation of the mooring and natatory ligament.<sup>[25,33]</sup>

The five deep tracts of the central band bifurcate to form medial and lateral sagittal septa (figure 3). The septa course anteriorly and deeply, surrounding the medial and lateral aspect of the digital flexor,<sup>[41]</sup> before crossing each other to insert sequentially into the flexor tendon sheath, interosseous fascia, the fascia of the transverse head of the adductor hallucis, the deep transverse metatarsal ligament and the base of the proximal phalanges via the plantar plate and collateral ligaments of the metatarsophalangeal joints.<sup>[39]</sup> Fibres from each septum also diverge medially and laterally to interdigitate with fibres from adjacent septa.<sup>[40]</sup> The most medial pair of septa also insert into the tibial and fibular sesamoids as well as the two heads of the flexor hallucis brevis muscle.<sup>[27]</sup>

The medial and lateral aspects of the central band of the plantar aponeurosis are continuous with the

intermuscular longitudinal septa and act to secure the plantar fascia to the deep structures of the foot.<sup>[27,42]</sup> Proximally, the lateral intermuscular septum attaches to the medial tubercle of the calcaneus, the calcaneocuboid ligament and the sheath of the peroneus longus. Distally, the septum divides to enclose the third plantar interosseous muscle, and inserts along the medial border of the fifth metatarsal shaft and the base of the proximal phalanx of the corresponding digit, where it becomes continuous with the medial sagittal septum of the fifth deep aponeurotic tract.<sup>[24]</sup>

The medial intermuscular septum, in contrast, is not as well defined and is generally reported to consist of a series of discontinuous bands.<sup>[32]</sup> Each band typically bifurcates to form medial and lateral divisions.<sup>[43]</sup> Proximally, the medial intermuscular septum has lateral insertions into the calcaneus, cuboid and short and long plantar ligaments,<sup>[24]</sup> blending with the interfascicular lamina of the calcaneal tunnel to attach to the medial surface of the calcaneus proximal to the border of quadratus plantae.<sup>[43]</sup> Distally, the medial intermuscular septum has attachments to the navicular, medial cuneiform and lateral aspect of the first metatarsal and blends with the tendons of tibialis posterior, flexor hallucis longus and the fascia of the abductor and flexor hallucis brevis.<sup>[25,32]</sup> The medial intermuscular septum also gives rise to the superficial origin of flexor hallucis brevis providing an indirect anchor to the medial calcaneal tubercle via the central component of the plantar fascia.<sup>[43]</sup>

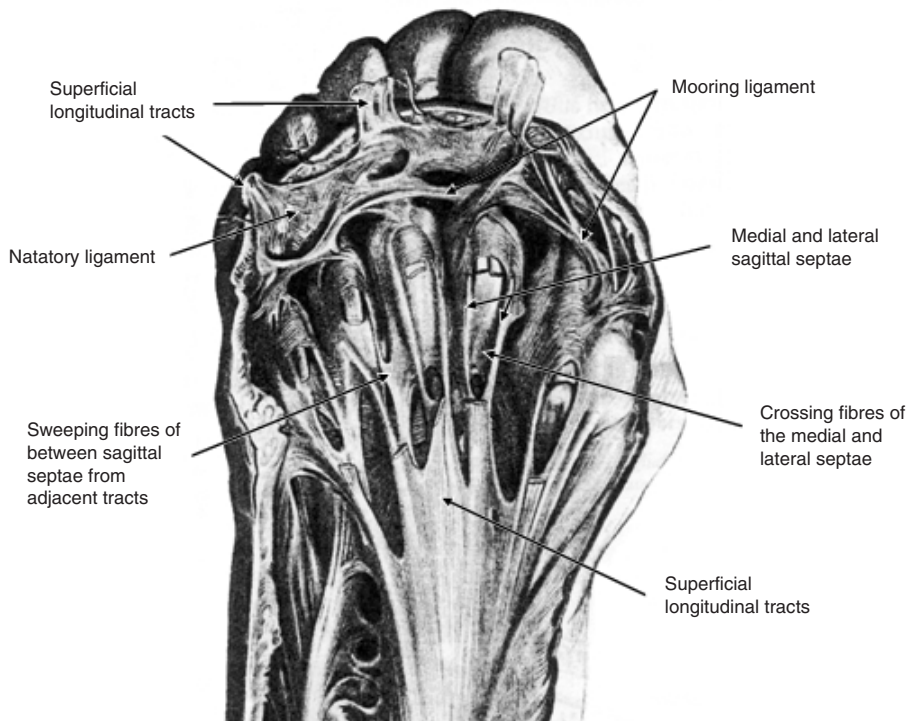
For the purpose of the current article, all future reference to the plantar fascia will implicitly refer to only the central aponeurotic band since it is considered the most significant, both structurally and functionally.

## 1.2 Histological Anatomy of the Plantar Fascia

While the gross anatomy of the plantar fascia is well documented, there is a relative dearth of information pertaining to its microscopic appearance. Typically described as a dense connective tissue structure, the fascia has been likened to both tendon and ligament.<sup>[44]</sup> Although Wright and Rennels<sup>[45]</sup> quote Straub (1950–1) in suggesting that the plantar fascia is histologically similar to ligaments of the foot, more recent studies have indicated that even morphologically similar ligaments are biochemically and histologically different.<sup>[46,47]</sup> It is recognised, therefore, that the histological appearance of the fascia is unlikely to be identical to either tendon or ligament.<sup>[48]</sup> Consequently, given the lack of pub-

lished information relating specifically to the plantar fascia, the following discussion briefly details the general histological appearance of connective tissue structures and, where pertinent, emphasises significant differences between tendon and ligament.

Similar to both tendon and ligament, the midsubstance of the plantar fascia is comprised of elongated fibrocytes embedded within an extracellular matrix consisting primarily of collagen fibres arranged in a crimped or wavy pattern.<sup>[26,49]</sup> Responsible for the production of collagen, the fibrocytes are arranged into longitudinal rows<sup>[26,50]</sup> and possess attenuated cell processes that surround collagen fibres and form gap junctions with fibrocytes from adjacent rows.<sup>[51,52]</sup> As a consequence of this arrangement, Benjamin and Ralphs<sup>[53]</sup> proposed that fibrocytes form a 3-dimensional communicating network



**Fig. 3.** The distal insertion of the plantar fascia. Note, for illustrative purposes, the superficial longitudinal tracts have been sectioned (reproduced from Sarrafian,<sup>[25]</sup> with permission).

that may be capable of sensing and responding to changes in load by modifying the composition of the extracellular matrix. Present in both tendon and ligament, fascia may have a greater sensory capacity since it contains more fibroblasts than tendon.<sup>[48]</sup> Thus, in addition to passively transmitting force, the plantar fascia may also act as an active sensory structure that is capable of modulating its composition in response to external demands.

### 1.2.1 Neuroanatomy

To the best of our knowledge, the neuroanatomy of the plantar fascia has not been documented within the literature. Ligaments, however, are neurologically well innervated structures and are characterised by both free nerve endings and encapsulated mechanoreceptors.<sup>[54,55]</sup> Predominantly located in the proximal and distal ends of ligament, strain-sensitive mechanoreceptors are thought to be responsible for sensing and responding to mechanical loading of tissue through reflexes. As a result of their location, mechanoreceptors have been considered to play a protective role only with extreme deformation or strain.<sup>[56,57]</sup> However, for any given load, the strain at the end of a ligament is significantly greater than at its midsubstance.<sup>[58-60]</sup> Consequently, mechanoreceptors may be more effective at detecting load when localised near the attachments of ligaments.

While the function of mechanoreceptors is controversial, free nerve endings are primarily believed to function as nociceptors, transmitting information on pain and inflammation.<sup>[61,62]</sup> Activated both mechanically and chemically,<sup>[62]</sup> the location of free nerve endings around osteoligamentous attachment sites also parallels the clinical location of pain in plantar fasciitis.<sup>[19]</sup> While free nerve endings may also act as high-threshold mechanoreceptors,<sup>[63]</sup> they may, in addition, play an important role in vasoregulation within connective tissue structures.<sup>[64,65]</sup>

### 1.2.2 Microcirculation

Both tendons and ligaments are relatively hypovascular structures.<sup>[66,67]</sup> While tendons receive blood vessels from both the myotendinous junction and paratenon,<sup>[68,69]</sup> these structures are absent in ligaments.<sup>[70]</sup> Occupying only 1.5% of the total area of the tendon,<sup>[71]</sup> experimental studies have demonstrated that the vascular anatomy of tendons and ligaments is not uniform, with different regions displaying distinct microvascular distributions.<sup>[72-74]</sup> In general, blood vessels form a conspicuous network within the outer surface of tendon and ligament<sup>[73,75]</sup> and give rise to only a limited number of deep intraligamentous vessels.<sup>[75,76]</sup> The blood vessels, however, do not penetrate the osteochondral insertion of tendons and ligaments, and subsequently leave an area of avascularity.<sup>[76-78]</sup> Avascular areas or 'critical zones' have also been reported within tendon<sup>[69,72,79]</sup> and ligament midsubstance<sup>[47,80]</sup> and have been associated with areas exposed to friction, compression or torsion.<sup>[67,81]</sup> Although the significance of such hypovascular regions to injury is controversial,<sup>[82-84]</sup> critical zones, such as osteochondral insertions, have been reported to be prone to advanced degenerative change.<sup>[85]</sup>

### 1.2.3 The Entesis

Despite the abundance of literature suggesting that plantar fasciitis commonly involves the en-

**Table 1.** Characteristic features of periosteal and fibrocartilaginous entheses

	Periosteal	Fibrocartilaginous
Pseudonyms	Fibrous, indirect	Direct, chondral
Location	Metaphyses or diaphyses of long bones  Structures with one degree of freedom	Epiphyses of long bones and short bones of tarsus and carpus  Structures with more than one degree of freedom
Insertion	Acute angle to bone	Right angle to bone
Histological appearance	Direct fibrous attachment blending into periosteum Sharpey's fibres are characteristic	Interposition of uncalcified and calcified fibrocartilaginous zones between midsubstance and bone



thesis, or proximal insertion of the aponeurosis,<sup>[13,86]</sup> few studies have investigated the microscopic structure of its attachment to the calcaneus. As described in table I, tendons and ligaments may possess either direct fibrocartilaginous or indirect periosteal attachments to bone depending on their osseous location.<sup>[87]</sup> The proximal attachment of the plantar fascia is fibrocartilaginous.<sup>[36,88,89]</sup> Histologically, fibrocartilaginous entheses are characterised by a sequence of four zones of tissue: the (i) dense fibrous tissue of the collagenous midsubstance, is replaced successively by (ii) uncalcified fibrocartilage, (iii) calcified fibrocartilage, and finally, (iv) bone.<sup>[90,91]</sup> In contrast to indirect periosteal attachments, periosteum is not a prominent feature of fibrocartilaginous attachments.<sup>[77,92]</sup> Snow et al.<sup>[36]</sup> illustrated that while superficial fibres of the plantar fascia were continuous with periosteum in neonates, the fascia was independent of periosteum in mature adults. Therefore, it is unlikely that plantar fasciitis represents an irritation or detachment of the periosteum arising from tension within the fascia, as proposed by Warren.<sup>[50]</sup>

In contrast to the midsubstance of ligaments, the ovoid cells that are typical of fibrocartilage are isolated within the extracellular matrix, and do not communicate with each other via gap junctions.<sup>[52,90]</sup> Calcified and uncalcified fibrocartilage are separated by a basophilic line, visible via light microscopy, termed the tidemark.<sup>[93]</sup> Smooth and devoid of vasculature,<sup>[77]</sup> the tidemark directly contrasts the characteristic interdigitations of the transition zone between calcified fibrocartilage and bone (figure 4).<sup>[94]</sup> The extent of calcification within the fibrocartilaginous region and the degree of osseous interdigitation is thought to reflect the tensile strength of the enthesis and is important in resisting shear.<sup>[88,95-97]</sup> By incorporating calcified and uncalcified fibrocartilaginous zones, direct attachments provide a gradual transition from hard to soft tissue, which help dissipate stress evenly.<sup>[98,99]</sup> In support of this concept,

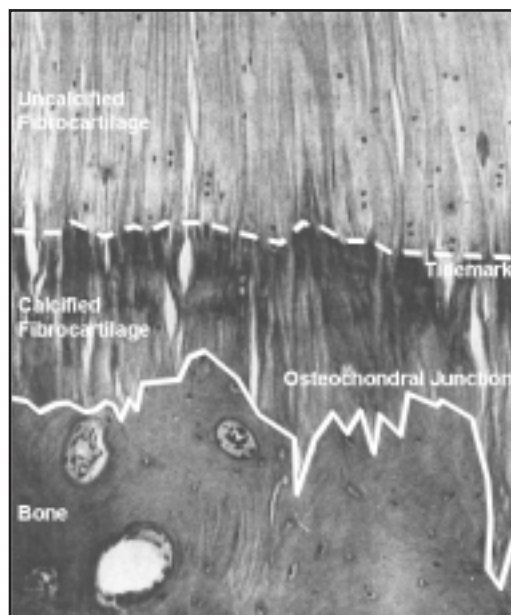
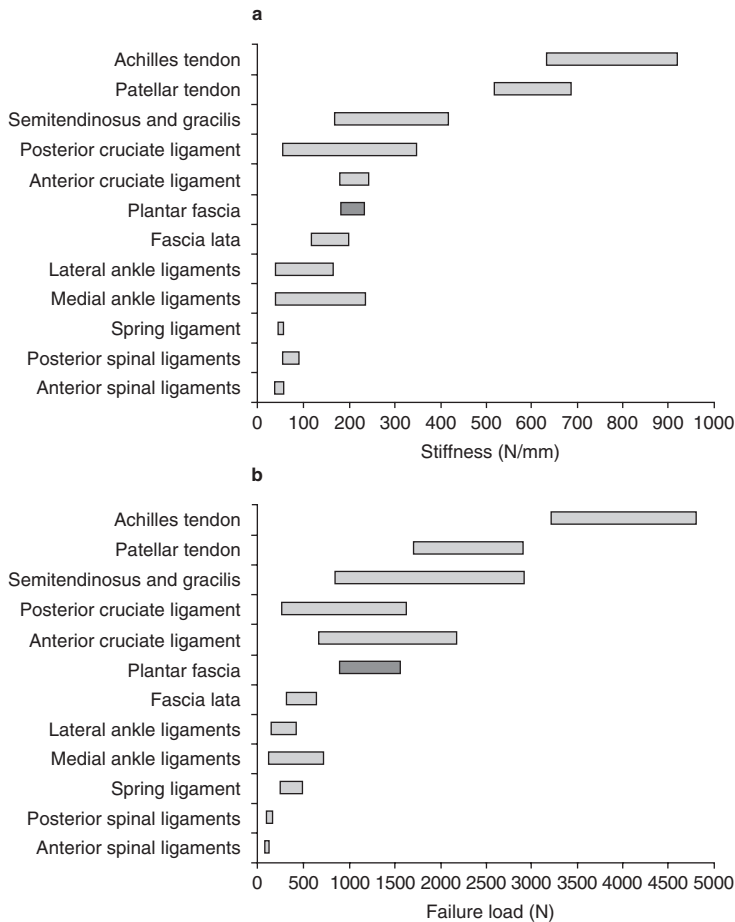


Fig. 4. A fibrocartilage enthesis.

the calcified zone of articular cartilage has been reported to be about 10-times less stiff than the underlying bone.<sup>[100]</sup> Paradoxically, recent investigations using backscattered electron imaging have indicated that calcified fibrocartilage at entheses has a greater mineral density than bone and, as such, may have a higher stiffness.<sup>[101-103]</sup> Age-related increases in the mineralisation of calcified fibrocartilage would tend to further increase the brittleness of the enthesis<sup>[102]</sup> and may potentially account for the higher incidence of insertional disorders, such as plantar fasciitis, in the elderly.<sup>[104]</sup>

While the purpose of the calcification gradient at fibrocartilaginous insertions is unclear, Benjamin et al.<sup>[77]</sup> observed that the amount of uncalcified fibrocartilage was primarily dependent on the specific anatomical location of the enthesis. Fibrocartilage insertions appear more prevalent in structures with more than one degree of freedom.<sup>[105,106]</sup> Furthermore, uncalcified fibrocartilage is present in greater quantities at the deep surface of attachment sites<sup>[106]</sup> and has also been demonstrated in 'wrap around'





**Fig. 5.** The (a) stiffness and (b) ultimate tensile strength of various human cadaveric tendons,<sup>[59,112,121,124,125]</sup> ligaments<sup>[47,59,123,126-131]</sup> and fascia (dark shaded bar)<sup>[59,111,132]</sup> reported within the literature.

tendons.<sup>[107,108]</sup> Fibrocartilage, therefore, appears to be located specifically at sites within tendons and ligaments that are subjected to bending, shear or compressive forces, or their combination.<sup>[70,109]</sup> The high concentration of proteoglycans and glycosaminoglycans, such as aggrecan, within fibrocartilage entheses lends further testament to their possible role in the redistribution of compressive or bending forces.<sup>[49,110]</sup> While plantar fasciitis is believed to result from excessive tensile force within the fascia,<sup>[50]</sup> these histological observations indicate that bending, shear and compression may have a potential role that has not been investigated.

## 2. Mechanical Properties of the Plantar Fascia

A thorough knowledge of the mechanical properties of the plantar fascia is a prerequisite for understanding its function. To date, studies investigating the mechanical properties of the plantar fascia have largely been limited to quasi-static loading in cadaver limbs. In such instances, the plantar fascia demonstrates a complex rheological behaviour, similar to both tendon and ligament, possessing time-dependent viscoelastic properties.<sup>[45]</sup>

## 2.1 Structural Properties

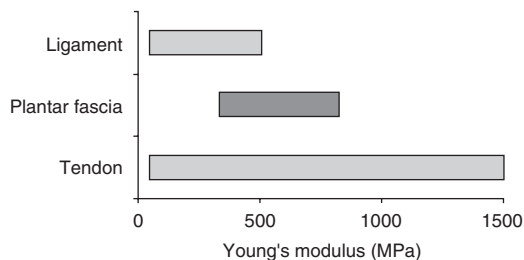
Kitaoka et al.<sup>[111]</sup> investigated the structural properties of 12 bone-plantar fascia-bone preparations tested at loading rates of 11.1, 111.2 and 1112.0 N/sec. Consistent with observations involving tendon and ligament,<sup>[112-114]</sup> the authors noted that loading rate had negligible effect on the stiffness of the plantar aponeurosis, and reported an average stiffness and ultimate strength of  $209 \pm 52$  N/mm and  $1189 \pm 244$ N, respectively. Figure 5 demonstrates the stiffness (N/mm) and ultimate strength (N) of various human connective tissue structures reported in the literature. As a whole, the plantar fascia appears to possess similar mechanical characteristics to the anterior cruciate ligament. However, the structural properties of connective tissue are dependent on several factors including not only the inherent properties of the tissue itself, but also the geometry of the tissue, the experimental methods employed and the type of enthesis tested.<sup>[115-117]</sup>

Bone-ligament-bone preparations typically produce higher stiffness and ultimate strength values than specimens taken from the tissue midsubstance.<sup>[59,118,119]</sup> Similarly, the rate of specimen loading has been reported to influence both the ultimate strength and the mode of specimen failure, with low loading rates resulting in reduced tissue strength and a predominance of insertional failures.<sup>[119,120]</sup> While the failure mode is primarily related to the density and strain-dependent behaviour of bone,<sup>[114,121,122]</sup> the orientation and distribution of load also profoundly affects the manner of tissue failure. Uniformly loaded specimens predominantly fail via rupture of the tissue midsubstance, while specimens loaded non-uniformly demonstrate a higher incidence of enthesis failure.<sup>[123]</sup> The preponderance of insertional failures observed by Kitaoka et al.<sup>[111]</sup> for plantar fascial specimens may, therefore, reflect inherent difficulties in the mechanical testing of bone-ligament-bone preparations, rather than actual struc-

tural deficits within the aponeurosis. Consequently, further research investigating the structural properties of the plantar fascia and its enthesis appears warranted.

## 2.2 Material Properties

In contrast to the structural properties of tissue, the material or tissue properties are independent of tissue shape or geometry, but are dependent on the complex interaction between the water content and composition of the tissue, the size, organisation and orientation of collagen fibres as well as their interaction with extracellular matrix.<sup>[133,134]</sup> Wright and Rennels<sup>[45]</sup> were the first to describe the tissue properties of the plantar fascia. Using specimens dissected free from their osseous attachment, the authors reported the modulus of elasticity to range between 342 and 822 MPa. These values fall within the upper ( $\sim 1500$  MPa) and lower ( $\sim 50$  MPa) limits cited for other human connective tissue structures tested *in vitro* (figure 6) and are greater than those published for fascial and ligamentous structures of the foot and lower leg.<sup>[44,131,135,136]</sup> The elastic modulus is, however, dependent on the applied load and, in animal studies, has been noted to increase until a stress of approximately 30 MPa is achieved.<sup>[137]</sup> It is likely, therefore, given the relatively low loads employed by Wright and Rennels,<sup>[45]</sup> that the cited range includes estimates based on loads from within the 'toe' region of the stress-strain curve. Conse-



**Fig. 6.** Tangent modulus (Young's modulus) for the linear region of the stress-strain curve of various human tendons,<sup>[116,119,124,125,141-144]</sup> ligaments<sup>[129-131,145,146]</sup> and the plantar fascia<sup>[45]</sup> (dark shaded bar) reported within the literature.

quently, comparisons with the literature should be made with respect to the upper limit of 822 MPa. Moreover, given the complex geometry of the plantar fascia, and the inherent difficulties in measuring the material properties of connective tissue structures,<sup>[138-140]</sup> the values reported by Wright and Renels<sup>[45]</sup> may provide only crude estimates of the plantar fascia's mechanical properties. Nevertheless, the material properties of the plantar aponeurosis appear to fall between those of tendon and ligament (figure 6).

Although *in vitro* studies provide a useful indication of the mechanical properties of connective tissue structures, the dimensions and the viscoelastic properties of cadaveric tissue may differ substantially to those of living humans. Kubo et al.<sup>[147]</sup> proposed that *in vitro* tests are not representative of tendon properties *in vivo*, since factors such as the water content and donor age of specimens are likely to modify the mechanical properties of tendon and ligament *in vitro*. In support, several studies have reported altered viscoelastic properties of tendon with varying water content.<sup>[148-150]</sup> However, the effect of donor age on the structural and material properties of tendon is less clear. While several *in vitro* studies have found no difference in the structural or material properties of tendon following maturation,<sup>[112,151-153]</sup> others have reported a decrease in either its stiffness, elastic modulus, or ultimate tensile strength with senescence.<sup>[116,123,125,154]</sup> The age-related deterioration in mechanical properties of tendon is believed, in part, to reflect an increase in non-reducible collagen cross-linking with age.<sup>[155]</sup> However, non-reducible collagen cross-linking results in greater mechanical stiffness in tendon,<sup>[156]</sup> a finding at odds with age-related observations in tendon and ligament properties tested *in vivo*.<sup>[157]</sup> Thus, age-related collagen cross-linking, does not account for the deterioration in mechanical properties of connective tissue observed in some studies.

Although the reasons for differential aging effects in various tissue structures is unknown,<sup>[152]</sup> degenerative changes, as seen in tendinopathy, may play an important role.<sup>[158]</sup> Tendinosis has been noted to reduce both the elastic modulus and tensile strength of tendon<sup>[159,160]</sup> and degenerative change is known to be more prevalent in older tendon specimens.<sup>[158,161]</sup> It is likely, therefore, that some specimens from elderly donors would possess varying degrees of tendon degeneration. Consequently, future studies evaluating the mechanical properties of the plantar fascia should employ histological evaluation to ensure specimens are free of degenerative change.

### 3. Mechanical Function of the Plantar Fascia

#### 3.1 Quasistatic Models of Plantar Fascial Function

*In vitro* studies have highlighted the importance of the plantar fascia in supporting the medial longitudinal arch during static stance. Cadaveric models have invariably shown a deterioration of arch structure with sectioning of the plantar fascia during simulated midstance.<sup>[162-165]</sup> While inducing minor triplanar movements within the tarsal complex,<sup>[163,166,167]</sup> fasciotomy has also been noted to cause transverse splaying of the metatarsals,<sup>[168]</sup> suggesting that the plantar fascia may form an integral part of both a transverse and longitudinal tie-bar system within the foot.<sup>[40]</sup>

During static stance, the medial longitudinal arch has been likened to a truss, with the plantar fascia acting as a tension element, or tie-bar connecting two compressive elements.<sup>[169]</sup> With weight bearing and internal tibial rotation, elongation of the arch is limited, in part, by tension within the plantar structures, which, in turn, place a compressive force through the osseous elements of the arch.<sup>[170]</sup> Thus, in theory, the plantar fascia is believed to form part

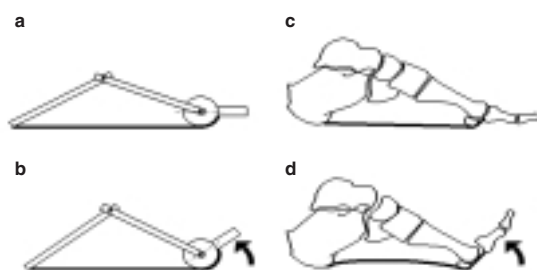
of a passive mechanism that is capable of modifying the stiffness of the arch in relation to the applied load.<sup>[171]</sup> In support, cadaveric studies have reported both increased fascial tension with progressive loading of the foot<sup>[172-174]</sup> and reduced arch stiffness with fasciotomy.<sup>[162,175]</sup> While all of the ligaments appear important in storing energy and providing support to the arch,<sup>[162,167]</sup> Huang et al.,<sup>[175]</sup> in a cadaver model, reported the greatest reduction in arch stiffness (25%) with resection of the plantar fascia when compared with both the spring and long and short plantar ligaments. The authors suggested, therefore, that the plantar fascia provided the largest contribution to arch maintenance. However, the arch still retained 65% of its original stiffness following resection of all four connective tissue structures, suggesting that other structures, such as the joint capsules, plantar ligaments and the geometry of the bones, themselves, may have the greatest effect on the stability of the medial longitudinal arch during static stance.

While elongation of the arch has been reported to increase tension within the plantar fascia,<sup>[170]</sup> the initial shape of the arch has also been suggested to influence the loading of the fascia.<sup>[176-178]</sup> Using a simple 2-dimensional model in which the fascia was represented as an elastic body connecting two rigid, pin-jointed elements of the foot, Hicks<sup>[169]</sup> indicated that tension within the plantar fascia was proportional to the span of the arch, with a low-arched structure resulting in greater fascial tension. While the plantar fascia would typically carry about 15% of the applied load in the 'normal-arched' foot,<sup>[179,180]</sup> the model implied that the fascia would have a greater contribution to maintenance of the arch in the 'flat' or low-arched foot, a finding consistent with cadaveric models in which arch deterioration was more pronounced in destabilised feet.<sup>[164]</sup> However, as with most cadaver models, mathematical representations have typically overestimated fascial strains observed *in vivo* with static loading of the tib-

ia,<sup>[45,181]</sup> suggesting that the models are too simplistic or that factors other than the plantar fascia may be involved in the maintenance of the medial longitudinal arch *in vivo*.

In contrast, Salathe et al.,<sup>[182]</sup> employing an elaborate 12-segment 3-dimensional model of the foot, indicated that fascial strains were negligible during midstance and were unaffected by small pronatory and supinatory movements of the foot. The model predicted that the greatest tension within the fascia occurred when the heel was raised from the supporting surface. While at odds with previous models, *in vivo* studies employing dynamic magnetic resonance imaging have reported similar findings, indicating that the plantar fascia was relaxed until heel lift when digital dorsiflexion initiated the so called 'windlass' mechanism.<sup>[183,184]</sup>

In a landmark study, Hicks<sup>[185]</sup> likened dorsiflexion of the digits to the function of a windlass. With dorsiflexion of the toes, the plantar fascia is wound around the metatarsal heads, thus shortening its effective length and increasing tension within the fascia (figure 7). During non-weightbearing, the mechanism invokes plantarflexion of the corresponding metatarsals and as such directly raises the arch. However, during static stance, plantarflexion of the



**Fig. 7.** Hick's windlass effect in the foot. (a) Mechanical windlass in which compressive struts are tethered by a tie connected to the windlass drum. (b) Rotation of the handle effectively shortens the tie and elevates the truss. (c) The windlass analogy applied to the foot. The calcaneus and metatarsals form the anterior and posterior compressive struts, which, in effect, are tethered by the plantar fascia via the metatarsophalangeal joint. The windlass drum is formed by metatarsal heads. (d) Digital dorsiflexion increases tension within the plantar fascia and results in elevation of the arch.

metatarsals is resisted by ground reaction force and elevation of the arch is achieved by the complex movement of supination and external rotation of the foot and lower limb. Thus, activation of the 'windlass' mechanism is believed to increase the stability of the arch in preparation for propulsion.<sup>[186,187]</sup> Clinically, the effect is most pronounced with dorsiflexion of the hallux due to the greater radius of curvature of the first metatarsal head<sup>[40,187]</sup> and the greater range of motion of the first ray.<sup>[188]</sup>

Hicks<sup>[185]</sup> attributed the mechanism solely to the plantar fascia since the effect was evident in paralysed and cadaveric feet and 'almost disappeared' with fasciotomy. In support, cadaveric studies have reported both a progressive loss of the windlass mechanism with fasciotomy<sup>[38]</sup> and an increase in arch height with dorsiflexion of the digits.<sup>[189]</sup> Although these observations do not preclude the potential role of muscle activity in the normal foot, Kappel-Bargas et al.<sup>[190]</sup> reported similar findings in an *in vivo* study, with hallux dorsiflexion resulting in either an immediate or delayed arch-raising effect in asymptomatic weightbearing feet. In the delayed-onset group, approximately 20° of hallux dorsiflexion was required before an increase in arch height was observed. Although consistent with studies of first metatarsophalangeal joint function,<sup>[191,192]</sup> the authors noted that the delayed group exhibited a greater magnitude of rearfoot eversion during walking and concluded that the delayed effect was most likely associated with an ineffective windlass mechanism. The study, however, failed to describe the method used to detect the onset of arch movement, an important limitation given that their data curves demonstrated no clear point of inflection. In addition, as with the majority of cadaver models,<sup>[38,186,193]</sup> the study evaluated the windlass effect while simultaneously applying vertical load to the rearfoot and forefoot. While the situation might resemble that encountered with high-heeled footwear,<sup>[193]</sup> it is not representative of barefoot gait.

Roentgen stereophotogrammetry has revealed different movement patterns in bones of the midfoot when the heel was raised by passive rather than active means.<sup>[194]</sup> Moreover, digital dorsiflexion occurs during terminal stance and is initiated once the heel is elevated from the supporting surface by the triceps surae.

Using a more representative model, Sharkey et al.<sup>[195]</sup> reported continued lowering of medial longitudinal arch in cadaveric specimens when tension within the Achilles tendon was used to reproduce heel positions typical of terminal stance. The authors indicated that stress within the plantar fascia was greater following elevation of the heel since loading of the Achilles tendon increased bending moments at the midfoot and effectively eliminated the effect of frictional resistance to collapsing of the arch. Carlson et al.,<sup>[196]</sup> using a similar model, indicated that fascial loading was dependent on both the tension within the Achilles tendon and the metatarsophalangeal joint angle in cadaveric feet. Modelling the position of the foot at 45% of the gait cycle, which is equivalent to 75% of stance, and applying loads of up to 500N through the Achilles tendon, dorsiflexion of the metatarsophalangeal joint beyond 30° was noted to produce fascial loads in excess of those of the Achilles tendon. Thus, the model implied that unified calf muscle activity and toe dorsiflexion might act to amplify the loading of the plantar fascia. However, the model did not consider the effect of the extrinsic flexor muscles of the foot in restraining arch collapse. The long digital flexors, and in particular the tibialis posterior, have been shown to have an arch-supporting effect during quasistatic testing.<sup>[189,197,198]</sup> Thordarson et al.<sup>[189]</sup> indicated that although the arch-supporting contribution of the tibialis posterior was relatively small during midstance, muscular support was equally important to that of the plantar fascia once the heel was elevated from the supporting surface.<sup>[195,199,200]</sup> Although the loading support offered by the intrinsic

muscles of the foot has not been quantified within the literature,<sup>[199]</sup> the intrinsic muscles are well positioned to further reduce fascial loading.<sup>[201]</sup> Normally quiescent during static bipedal stance,<sup>[202-204]</sup> the intrinsic muscles have also been shown to be active throughout the midstance and propulsive periods of gait particularly following heel lift.<sup>[204-206]</sup>

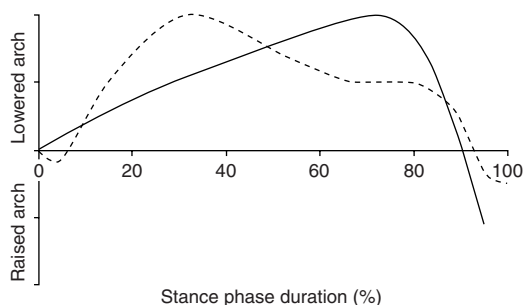
The plantar fascia has also been proposed to function in a reverse windlass capacity during stance, with lowering of the arch resulting in a plantarflexion moment at the digits.<sup>[185]</sup> The plantarflexory moment, in turn, is believed to provide the toes with a plantar-directed force and assist the extrinsic flexors in stabilising the digits during terminal stance.<sup>[33,40]</sup> In support, *in vitro* studies have reported both a decrease in force beneath the digits,<sup>[199,207]</sup> and an increase in hallux dorsiflexion with fasciotomy.<sup>[208]</sup> Sharkey et al.<sup>[207]</sup> also showed that sectioning of the fascia in a cadaver model resulted in increased metatarsal strains and contracture of the digits once the long digital flexors were loaded. Digital clawing has also been reported, clinically, following disruption of the plantar fascia.<sup>[33,209]</sup> While gait analysis has confirmed the importance of the toes as load-bearing structures during dynamic activities such as walking,<sup>[210,211]</sup> digital loading is negligible during static stance suggesting that digital function is primarily influenced by muscular action.<sup>[212]</sup> Thus, the passive role of the reverse windlass mechanism in digital stabilisation has probably been overstated within the literature.

### 3.2 Dynamic Function of the Medial Longitudinal Arch During Gait

While the role of the plantar fascia has largely been inferred from static loading of cadaver specimens, the function of the fascia may also be estimated from the movement of the medial longitudinal arch within the sagittal plane.<sup>[45]</sup> *In vivo* measures of arch movement have indicated that, on average, the arch undergoes a 6mm change in length during

gait.<sup>[206]</sup> Equivalent to 10° of angular movement of the arch,<sup>[213,214]</sup> estimates as large as 20° have also been reported during walking in normal<sup>[215]</sup> and pathological groups.<sup>[216]</sup>

Early studies, using surface-mounted uniaxial goniometry in combination with electromyography and measures of ground reaction force, have indicated that the medial longitudinal arch undergoes four phases of sagittal movement during stance, consisting of alternating periods of elongation and shortening (figure 8).<sup>[206,217]</sup> Kayano<sup>[206]</sup> speculated that the vertical load associated with the contact phase of gait resulted in a profound initial lengthening of the arch that was passively resisted by ligamentous structures of the foot since arch-supporting muscles were inactive during this period. The subsequent shortening of the arch noted to occur throughout midstance was proposed to reflect an effective decrease in load coupled with activation of arch supporting muscles such as the long and short digital flexors. At heel lift, the relatively small increase in arch length was attributed to increases in both calf muscle activity and vertical load. The rapid decrease in arch length during late terminal stance was attributed to the windlass action of the plantar aponeurosis, since rapid dorsiflexion of the hallux was noted to occur during this period.



**Fig. 8.** The pattern of sagittal movement reported for the medial longitudinal arch during the stance phase of gait. Studies employing surface mounted goniometry (dashed line) indicate the arch undergoes alternating periods of elongation and shortening throughout stance.<sup>[206,217]</sup> However, studies employing fluoroscopy<sup>[218]</sup> and optical-based motion analysis<sup>[219-221]</sup> have typically reported a continued elongation of the arch until 75–80% of stance (solid line).



More recent investigations using 2- and 3-dimensional motion analysis, however, have failed to replicate the arch shortening noted by earlier studies during the midstance phase of gait. In contrast, a gradual decrease in arch height has been reported following heel contact, with the nadir occurring after heel lift, at approximately 75–85% of stance (figure 8).<sup>[219-221]</sup> It is unclear why differences in arch motion during midstance have been reported between studies employing goniometry and optical motion analysis techniques. While both techniques are likely to experience skin movement artefact, goniometry may be prone to larger error due to its greater mass. However, comparisons across studies are difficult since none have stated the physical characteristics of the skin markers employed nor the measurement resolution of the equipment used.

Consistent with earlier investigations,<sup>[206,217]</sup> studies using 3-dimensional motion analysis have reported a rapid and substantial increase in arch height during the final 10–15% of stance.<sup>[219-221]</sup> Although Cashmere et al.<sup>[221]</sup> attributed the rise in arch height purely to the windlass action of the plantar aponeurosis, they did not incorporate measures of digital movement. In contrast, studies incorporating simultaneous measures of arch and digital kinematics during gait have indicated that approximately 20° of digital dorsiflexion is required before an increase in arch height is evident.<sup>[222]</sup> The increase in arch height associated with the windlass effect, has been reported to coincide with peak intrinsic muscle activity,<sup>[217]</sup> reduced activity in the triceps surae,<sup>[219,223]</sup> reduced vertical loading,<sup>[206,221]</sup> peak horizontal propulsive force,<sup>[206]</sup> ankle plantarflexion<sup>[220]</sup> and the commencement of double limb support.<sup>[224,225]</sup> Thus, the elevation of the arch that transpires late in terminal stance is not purely associated with the plantar fascia and, as such, is unlikely to be the result of high plantar fascial load.

To date, the majority of studies investigating the function of the medial longitudinal arch during gait

have used skin-mounted markers to obtain kinematic estimates of skeletal movement. While such techniques undoubtedly provide an insight into the mechanics of the foot, movement of skin relative to the underlying bone has been cited as the most critical factor limiting the measurement resolution of detailed joint movements.<sup>[226]</sup> Consequently, motion analysis employing skin-mounted markers may give rise to unacceptable error, especially when evaluating small joint movements such as those of the medial column of the foot.<sup>[227]</sup>

### 3.3 Fascial Loading During Gait

The load borne by the plantar fascia during the dynamics of gait has been sparsely reported within the literature.<sup>[228]</sup> In one of the few studies performed to date, Scott and Winter<sup>[229]</sup> employed a force platform in conjunction with an optical motion analysis system to predict internal loading patterns of the plantar fascia in runners. The subsequent 2-dimensional, 4-segment model of the lower extremity assumed that 50% of the midtarsal joint moment was borne by the plantar fascia; which was modelled to extend from the calcaneus to the distal aspect of the fifth metatarsal. Peak fascial loads in the order of 2.8-times bodyweight were reported during the midstance and early propulsive periods of gait. While Wren et al.<sup>[119]</sup> proposed that loading of the Achilles tendon *in vivo* was similar to that for *in vitro* models at failure, the predicted load exceeds the ultimate tensile strength of the plantar fascia tested *in vitro*.<sup>[45,111]</sup> Thus, the internal loading of the plantar fascia was most likely overestimated by the model.

Gefen<sup>[230]</sup> determined fascial loads in the order of 1.5-times bodyweight (1000N) using fluoroscopy-derived kinematic data in combination with a simplistic 2-dimensional passive model of the foot in which the plantar fascia was represented as connecting two rigid, pin-jointed elements of the foot. Maximal strains of 11–12% were predicted to occur

during the early propulsive period of stance; a value 5-times greater than that estimated by an identical model during quiet static stance.<sup>[45]</sup> While comparable with the ultimate tensile strain (15%) of tendon and ligament tested *in vitro*,<sup>[142]</sup> it is likely that the model overestimated fascial strain by ignoring the loadbearing capacity of the intrinsic and extrinsic muscles of the foot. In fact, studies of human tendons have reported *in vivo* strains of only 5% during maximum isometric muscle contraction; a value consistent with the upper limit of the 'toe' region of the stress strain curve.<sup>[231-234]</sup>

Erdemir et al.<sup>[235]</sup> estimated considerably lower fascial loads using a dynamic cadaveric model in which a fibre optic cable was embedded within the plantar fascia. Peaking at 80% of stance, fascial loads were found to approximate bodyweight (538N) and are equivalent to 45% of the ultimate tensile strength reported for the plantar fascia. While suggestive of a safety factor similar to *in vivo* estimates of the Achilles tendon,<sup>[234]</sup> Malaviya et al.<sup>[236]</sup> demonstrated that even during vigorous activity, animal tendons developed *in vivo* forces that, on average, extended up to only 30% of their failure load. It is likely, therefore, that dynamic models investigating the function of the plantar fascia have considerably overestimated fascial load. In light of the findings in tendon, it seems reasonable to speculate that the plantar fascia would possess a similar safety factor to elastic storage tendons and probably experience strains in the order of 5% during freely selected walking. However, further research regarding the internal loading of the foot and the load borne by the plantar fascia is required before such deductions can be drawn with assurance.

#### 4. Histopathology of Plantar Fasciitis

The pathogenesis of plantar fasciitis is not well understood. As with chronic tendon disorders, a lack of consistent nomenclature regarding histopathological findings has limited progress in understand-

ing the pathological basis of plantar fasciitis. However, there is a general consensus within the literature that mechanical overload and excessive strain produce microscopic tears within the fascia, which subsequently invoke an inflammatory repair process.<sup>[28,50]</sup> The normative repair process is thought to be inhibited by continued microtrauma arising from repeated heel strike,<sup>[237]</sup> resulting in chronic inflammation of the fascia.<sup>[238-240]</sup> Thus, plantar fasciitis is thought by some investigators to share a similar pathogenesis to tendinitis (tendon inflammation)<sup>[239,241]</sup> and insertitis (inflammation of tendon insertion).<sup>[242]</sup>

Table II summarises the main histological features reported for plantar fasciitis following surgical resection in chronic heel pain. Collagen degeneration with fibre disorientation, increased mucoid ground substance, angiofibroblastic hyperplasia and calcification are the most frequently reported findings. While all studies recount various combinations of degenerative change within the plantar fascia, active inflammatory infiltrate, as indicated by the presence of polymorphonuclear leukocytes, lymphocytes or macrophages, has been rarely reported. Hence, inflammation does not appear to be a predominant feature of plantar fasciitis, especially in older, sedentary individuals.<sup>[19]</sup> Similar degenerative change, in the absence of inflammation, has been reported in chronic tendon disorders.<sup>[161,243,244]</sup> Consequently, the mechanism underlying the development of plantar fasciitis may be related to advanced fascial degeneration,<sup>[12,13]</sup> and more akin to that of tendinosis (tendon degeneration) than that of tendinitis or insertitis.

Enthesal fibrocartilage, in particular, appears prone to degenerative change.<sup>[99,247,248]</sup> Resembling the change seen in articular cartilage during the early stages of osteoarthritis, degeneration is characterised by cartilage cell clustering and the formation of longitudinal fissures within fibrocartilage.<sup>[99,110]</sup> Ossification within degenerated entheses

**Table II.** Histopathological findings in plantar fasciitis

Study	Subjects	Method	Histological findings
Snider et al. <sup>[239]</sup>	9 males and 1 amputated control limb	Light microscopy	Four variations noted: collagen degeneration (100% of cases) angiofibroblastic hyperplasia (56% of cases) chondroid metaplasia (22% of cases) matrix calcification (11% of cases)
Leach et al. <sup>[245]</sup>	15 athletes	Not reported	Chronic granulomatous tissue Mucoid degeneration in some instances Two cases of partial rupture Local inflammatory reaction
LeMelle et al. <sup>[240]</sup>	2 subjects	Electron microscopy	Subject 1: fibrocartilaginous degeneration fibrovascular hyperplasia Subject 2: irregular staining fraying of collagen fibres no fibrosis or lymphocytic infiltration
Schepis et al. <sup>[238]</sup>	25 athletes	Not reported	Degeneration of collagen Collagen metaplasia Calcification
Tountas and Fornasier <sup>[19]</sup>	21 sedentary subjects and 5 amputated control limbs	Not reported	Varying amounts of: collagen degeneration mucoid degeneration fibrinoid degeneration fibrovascular proliferation partial rupture No active inflammation
Lemont et al. <sup>[246]</sup>	50 heel spur samples	Not reported	No abnormality (10 samples) Mucoid degeneration with fibre fragmentation (16 samples) Vascular proliferation of the bone marrow (12 of 16 samples) Calcification with fragmentation (2 samples) No evidence of inflammation

fibrocartilage has also been demonstrated in tendon and ligament entheses and often presents, radiographically, as spurs.<sup>[108,249]</sup> Typically found immediately deep to the plantar fascia at the dorsal surface of the enthesal fibrocartilage,<sup>[248,250]</sup> plantar heel spurs develop via a process of intramembranous and chondroid ossification, in which connective tissue and fibrocartilage are changed directly into bone.<sup>[19,248]</sup> Given the importance of fibrocartilage in redistributing compressive, bending and shear forces, plantar heel spurs may not be the result of excessive traction within the fascia, but may instead develop in response to bending at the attachment site. Analogous to the role of compression in remodelling of bone,<sup>[251]</sup> plantar heel spurs may provide a buttressing effect to the fascia by effec-

tively minimising bending at the insertion. The significance of heel spurs in the development of plantar fasciitis, however, is uncertain since the phenomenon has also been reported, albeit to a lesser extent, in asymptomatic individuals and is more prevalent with advancing age.<sup>[252,253]</sup>

In reviewing the microscopic appearance of tendon injury, Józsa and Kannus<sup>[242]</sup> likened the histopathology of plantar fasciitis to that of insertitis, indicating that degeneration at the enthesis was accompanied by an inflammatory reaction within the surrounding paratenon. While Gibbon and Long<sup>[21]</sup> anecdotally reported that the plantar fascia was surrounded by a loose connective tissue sheath similar to paratenon, the present review was unable to locate a single anatomical study that could confirm the

existence of a paratenon-like structure in fascia. As highlighted by Benjamin and Ralphs,<sup>[70]</sup> an equivalent structure has not been documented in ligament. Given that inflammation within tendon primarily involves the paratenon,<sup>[254-256]</sup> further research regarding the presence of a paratenon-like structure in the plantar fascia appears warranted.

The absence of inflammatory infiltrate in chronic forms of plantar fasciitis, however, may represent a late sequela of chronic inflammation.<sup>[257]</sup> Hess et al.<sup>[258]</sup> proposed that degenerative change proceeds through a series of acute and chronic inflammatory phases before degeneration develops. In support of this concept, studies involving animal tendons have suggested that inflammation may play an important role early in the disease process.<sup>[259,260]</sup> However, degenerative lesions within the plantar fascia have also been reported, albeit to a lesser extent, in amputated limbs without a history of heel pain.<sup>[19]</sup> Similarly, while representing the end result of degenerative change, rupture of the plantar fascia is not always preceded by symptoms of plantar fasciitis.<sup>[261-263]</sup> While these observations suggest that degenerative change within the plantar fascia may proceed asymptotically, they also raise the possibility that inflammation and degeneration do not represent a continuum of disease but reflect two independent, although often coexisting, processes.<sup>[161,264]</sup>

While the mechanism leading to degenerative change is likely to be multifactorial in nature, mechanical overload is thought to be a major aetiological factor.<sup>[244,265]</sup> Animal studies have demonstrated an association between mechanical overload and tendon degeneration.<sup>[160,259]</sup> However, repeated mechanical loading, in itself, is not sufficient to induce tendon injury in animal models.<sup>[266,267]</sup> Consequently, vascular impairment with subsequent hypoxia and metabolic disturbance is also thought to play a key role.<sup>[85,268]</sup> Experimental studies have demonstrated that degenerative change may be clin-

ically induced by inhibiting vascular perfusion within animal tendon.<sup>[269]</sup> Similarly, microcirculatory studies have revealed poorly vascularised areas, or 'critical zones', within human tendons that are prone to degeneration and spontaneous rupture.<sup>[69,72,84]</sup> In addition, free radicals, induced by the reperfusion of ischaemic areas within tendon<sup>[85]</sup> and exercise-induced hyperthermia<sup>[270]</sup> have also been suggested to contribute to degenerative change. While collagen degeneration may also have a genetic link through ABO blood grouping,<sup>[271-273]</sup> recent studies have failed to confirm this association.<sup>[274,275]</sup> Genetic factors may, however, provide an interesting area for future research into plantar fasciitis, especially given the relationship between heel pain, spondyloarthropathy and HLA genetic markers.<sup>[23]</sup>

## 5. Aetiological Factors in Plantar Fasciitis

Although the aetiology of plantar fasciitis is likely to be multifactorial, mechanical overload has been cited as the principal factor involved in the development of the condition.<sup>[276,277]</sup> As with most overuse-type injuries,<sup>[278,279]</sup> both intrinsic and extrinsic risk factors have been anecdotally reported to precipitate the development of plantar fasciitis.<sup>[4,28,280,281]</sup> While the onset of musculoskeletal injuries of the lower limb has largely been attributed to extrinsic factors,<sup>[279]</sup> Taunton et al.<sup>[280]</sup> proposed that intrinsic factors, such as pes planus and subtalar joint pronation, provided the most significant contribution to the development of plantar fasciitis (table III).

Although a detailed examination of each risk factor is beyond the scope of the current article, the basic premise underlying most intrinsic factors is embodied by a lowering of the medial longitudinal arch, or an increase in its loading, or both. While high-arched foot types have been suggested to increase the relative load borne by the plantar fascia by presumably reducing shock attenuation,<sup>[177]</sup> lowering of the medial longitudinal arch is thought to

**Table III.** Proposed risk factors in plantar fasciitis<sup>a</sup>

<b>Intrinsic factors</b>
Age
Bodyweight/body mass index
Pes planus/low arch
Pes cavus/high arch
Subtalar joint pronation
Unequal limb length
Tibial and subtalar varum
Femoral/tibial torsion
Reduced ankle dorsiflexion/tight Achilles tendon
Increased ankle plantarflexion
Weak ankle plantarflexors
Heel pad characteristics
<b>Extrinsic factors</b>
Footwear
Surface properties
Activity type
Activity level
frequency
intensity
duration
Trauma

a No single factor has been reliably identified across studies.<sup>[2-4,104,280,282-291]</sup>

induce greater tensile strain within the plantar fascia leading to microtearing. However, few empirical studies have demonstrated an association between plantar fasciitis and changes in either the shape of the arch or loading of the foot during gait. The following section outlines the evidence for altered loading and abnormal arch mechanics in plantar fasciitis.

### 5.1 Ground Reaction Force in Plantar Fasciitis

Gait analysis has revealed inconsistent findings regarding the effect of plantar fasciitis on lower-limb loading. Although ground reaction and transient impulsive forces have been anecdotally linked with plantar fasciitis<sup>[292]</sup> and have been shown to increase internal compressive stress within the heel,<sup>[293]</sup> Liddle et al.<sup>[294]</sup> observed no difference between symptomatic and asymptomatic limbs of

23 patients with respect to the magnitude and timing of the heel strike transient or the first vertical force maximum. They subsequently proposed that ground reaction force did not contribute to the development of heel pain. Other studies, however, have reported a substantial change in the ground reaction force profile of patients with plantar fasciitis. Compared with matched control subjects, a relative flattening of the normally double-humped vertical ground reaction force profile has been reported, suggesting patients with heel pain adopted a less energetic gait pattern in a specific attempt to reduce the regional loading of the heel.<sup>[295-297]</sup> While our work tends to support these conclusions,<sup>[298]</sup> Spears et al.<sup>[293]</sup> proposed loading of the foot in a horizontal or flatfooted position resulted in the localisation of stress at the fascia insertion. However, the majority of studies specifically evaluating the regional loading of the foot have indicated that heel kinetics remain unaltered in plantar fasciitis.<sup>[296,299-302]</sup> Kelly et al.<sup>[300]</sup> found no difference in either the contact duration or the peak pressure beneath the heel of subjects with and without heel pain. While finite element modelling of the heel pad has suggested that plantar pressures are not necessarily representative of internal compressive stress,<sup>[293]</sup> both Katoh et al.<sup>[296,299]</sup> and Bedi and Love<sup>[301]</sup> confirmed that hindfoot impulses, derived from a force platform, were unchanged in plantar fasciitis. However, they disagreed regarding the loading of the midfoot and forefoot in heel pain. Katoh et al.<sup>[296]</sup> reported increased midfoot and lowered forefoot impulses in patients with plantar fasciitis. Bedi and Love<sup>[301]</sup> found the exact opposite, with plantar fasciitis invoking lowered midfoot impulses at the expense of heightened forefoot impulses. Consequently, there is little consensus regarding the effect of plantar fasciitis on the loading pattern of the involved limb during gait. Given that clinical doctrine suggests mechanical overload is essential to the development of plantar fasciitis, there is a need to establish



whether ground reaction force and regional loading of the foot is altered in plantar fasciitis.

## 5.2 Arch Mechanics in Plantar Fasciitis

While the link between altered mechanical loading and plantar fasciitis is tenuous, clinical reports regarding plantar fasciitis and foot function abound.<sup>[13,277,303]</sup> Although clinical associations between heel pain and high-arched foot types have been made,<sup>[13]</sup> the weight of literature has focused on the role of pes planus foot types and foot pronation, in the development of plantar fasciitis.<sup>[280,304-306]</sup> However, in a recent retrospective analysis of 2002 patients with running injuries, Taunton et al.<sup>[2]</sup> reported that only 30 of the 159 patients (19%) with plantar fasciitis had an abnormal arch structure (high or low) when judged subjectively. While Rano et al.<sup>[290]</sup> reported a higher percentage (46%) when arch shape was based on static weightbearing radiographs, the arch profile of the 49 patients did not significantly differ from that of control subjects. Similarly, Rome et al.<sup>[3]</sup> found no difference in the arch shape of patients with and without plantar heel pain when direct measures of navicular height were employed during standing.

Other radiographic studies, in contrast, have indicated a possible link between foot structure and plantar fasciitis. Prichasuk and Subhadrabandhu<sup>[307]</sup> observed a significantly lower calcaneal pitch in a radiographic study of 82 patients with heel pain, suggesting that pes planus was an important factor in the development of plantar fasciitis. Shama et al.<sup>[308]</sup> drew similar conclusions in a retrospective review of 1000 patient radiographs in which radiographic evidence of foot pronation was found in 81% of their 52 patients with heel pain. However, studies using surface-mounted markers have found that neither foot pronation nor arch height were able to discriminate between subjects with and without heel pain.<sup>[282-284]</sup> Similarly, we recently found no difference in the sagittal movement or dynamic

shape of the arch in subjects with and without plantar fasciitis, indicating that abnormal sagittal plane mechanics of the arch was not associated with chronic plantar fasciitis.<sup>[218]</sup> However, fascial thickness was correlated with arch shape in the symptomatic foot, highlighting the possibility that, once the condition is present, sagittal arch mechanics may influence fascial strain and, as such, the severity of plantar fasciitis. Given the presence of fibrocartilage at the fascial enthesis, the role of bending, shear or compressional force in the development of plantar fasciitis cannot be readily discounted. Non-uniform loading has recently been demonstrated in tendon entheses, with regions exposed to low or compressive strains noted to coincide with sites prone to degenerative change.<sup>[309,310]</sup> Thus in tendon, 'stress-shielding' rather than tensile failure *per se*, has been implicated in the development of tendon injury.<sup>[157,311]</sup> While there is evidence that the deep surface of the fascial enthesis is prone to degenerative change,<sup>[248,250]</sup> the presence of differential strain within the plantar fascia has not been established within the literature. Given the histological similarities between plantar fasciitis and tendinosis, further research specifically evaluating the role of 'stress-shielding' and compressional force in the development of plantar fasciitis appears warranted.

## 6. Conclusions

Similar to tendinopathy, plantar fasciitis is characterised by a marked degeneration of collagen in which inflammation is not a predominant feature. While clinical doctrine has implicated biomechanical factors that promote excessive tensile strain within the plantar fascia as paramount to the development of plantar fasciitis, scientific support for this premise is limited. Research is needed to determine the significance of tensile stress, as well as non-uniform loading of the plantar fascia, including bending, shear and compression, in the development of plantar fasciitis. Similarly, other factors including



an inherent or age-related degeneration of the fascia also need to be considered.

## Acknowledgements

The authors have no conflicts of interest that are directly related to the contents of this review and no financial support was received for the preparation of this manuscript. Dr Wearing was funded by a Strategic Links with Industry Grant with co-contributions from the Queensland University of Technology and Medical Benefits Fund.

## References

- Michelson JD. Heel pain: when is it plantar fasciitis? *J Musculoskelet Med* 1995; 12: 22-6
- Taunton JE, Ryan MB, Clement DB, et al. A retrospective case-control analysis of 2002 running injuries. *Br J Sports Med* 2002; 36: 95-101
- Rome K, Howe T, Haslock I. Risk factors associated with the development of plantar heel pain in athletes. *Foot* 2001; 11: 119-25
- Rome K. Anthropometric and biomechanical risk factors in the development of plantar heel pain: a review of the literature. *Phys Ther Rev* 1997; 2: 123-34
- Atkins D, Crawford F, Edwards J, et al. A systematic review of treatments for the painful heel. *Rheumatology* 1999; 38: 968-73
- O'Malley MJ, Page A, Cook R. Endoscopic plantar fasciotomy for chronic heel pain. *Foot Ankle Int* 2000; 21: 505-10
- Davis PF, Severud E, Baxter DE. Painful heel syndrome: results of nonoperative treatment. *Foot Ankle Int* 1994; 15: 531-5
- Wolgin M, Cook C, Graham C, et al. Conservative treatment of plantar heel pain: long-term follow-up. *Foot Ankle Int* 1994; 15: 97-102
- Martin RL, Irrgang JJ, Conti SF. Outcome study of subjects with insertional plantar fasciitis. *Foot Ankle Int* 1998; 19: 803-11
- Crawford F, Atkins D, Edwards J. Interventions for treating plantar heel pain. *Cochrane Database Syst Rev* 2000; (3): CD000416
- Davies MS, Weiss GA, Saxby TS. Plantar fasciitis: how successful is surgical intervention? *Foot Ankle Int* 1999; 20: 803-7
- Young CC, Rutherford DS, Niedfeldt MW. Treatment of plantar fasciitis. *Am Fam Physician* 2001; 63: 467-78
- Gill LH. Plantar fasciitis: diagnosis and conservative management. *J Am Acad Orthop Surg* 1997; 5: 109-17
- Gill LH, Kiezbak GM. Outcome of nonsurgical treatment for plantar fasciitis. *Foot Ankle Int* 1996; 17: 527-32
- Pfeffer G, Bacchetti P, Deland J, et al. Comparison of custom and prefabricated orthoses in the initial treatment of proximal plantar fasciitis. *Foot Ankle Int* 1999; 20: 214-21
- Selth CA, Francis BE. Review of non-functional plantar heel pain. *Foot* 2000; 10: 97-104
- Barrett SL, O'Malley R. Plantar fasciitis and other causes of heel pain. *Am Fam Physician* 1999; 59: 2200-6
- Karr SD. Subcalcaneal heel pain. *Orthop Clin North Am* 1994; 25: 161-75
- Tountas AA, Fornasier VL. Operative treatment of subcalcaneal pain. *Clin Orthop* 1996; 332: 170-8
- Singh D, Angel J, Bentley G, et al. Plantar Fasciitis. *BMJ* 1997; 315: 172-5
- Gibbon WW, Long G. Ultrasound of the plantar aponeurosis (fascia). *Skeletal Radiol* 1999; 28: 21-6
- Schroeder BM. American College of Foot and Ankle Surgeons: the diagnosis and treatment of heel pain. *Am Fam Physician* 2002; 65: 1686-8
- McGonagle D, Marzo-Ortega H, O'Connor P, et al. The role of biomechanical factors and HLA-B27 in magnetic resonance imaging-determined bone changes in plantar fascia enthesopathy. *Arthritis Rheum* 2002; 46: 489-93
- Mitchell IR, Meyer C, Krueger WA. Deep fascia of the foot: anatomical and clinical considerations. *J Am Podiatr Med Assoc* 1991; 81: 373-8
- Sarrafian SK. Anatomy of the foot and ankle: descriptive, topographic, functional. New York: JB Lippincott Company, 1983
- Newell SG, Miller SJ. Conservative treatment of plantar fascial strain. *Phys Sportsmed* 1977; 5: 68-73
- Hedrick MR. The plantar aponeurosis. *Foot Ankle Int* 1996; 17: 646-9
- Kaya BK. Plantar fasciitis in athletes. *J Sport Rehabil* 1996; 5: 305-20
- Cralley JC, Schubert JM, Fitch KL. The deep band of the plantar aponeurosis of the human foot. *Anat Anz* 1982; 152: 189-97
- Hiramoto Y. Shape of the fibular part of the plantar aponeurosis in Japanese. *Okajimas Folia Anat Jpn* 1983; 60: 329-37
- Dylevský I. Connective tissues of the hand and foot. *Acta Univ Carol Med Monogr* 1988; 127: 5-195
- Draves DJ. Anatomy of the lower extremity. Baltimore (MD): Williams and Wilkins, 1986
- Pontious J, Flanigan KP, Hillstrom HJ. Role of the plantar fascia in digital stabilization: a case report. *J Am Podiatr Med Assoc* 1996; 86: 43-7
- Waller Jr JF, Maddalo A. The foot and ankle linkage system. In: Nicholas JA, Hershman EB, editors. The lower extremity and spine in sports medicine. St Louis (MO): CV Mosby, 1986: 413
- Viel E, Esnault M. The effect of increased tension in the plantar fascia: a biomechanical analysis. *Physiother Theory Pract* 1989; 5: 69-73
- Snow SW, Bohne WH, DiCarlo E, et al. Anatomy of the Achilles tendon and plantar fascia in relation to the calcaneus in various age groups. *Foot Ankle Int* 1995; 16: 418-21
- Hawkins BJ, Langermen RJ, Gibbons T, et al. An anatomic analysis of endoscopic plantar fascia release. *Foot Ankle Int* 1995; 16: 552-8
- Thordarson DB, Kumar PJ, Hedman TP, et al. Effect of partial versus complete plantar fasciotomy on the windlass mechanism. *Foot Ankle Int* 1997; 18: 16-20
- Bojsen-Møller F, Flagstad KE. Plantar aponeurosis and internal architecture of the ball of the foot. *J Anat* 1976; 121: 599-611

40. Stainsby GD. Pathological anatomy and dynamic effect of the displaced plantar plate and the importance of the integrity of the plantar plate-deep transverse metatarsal ligament tie-bar. *Ann R Coll Surg Engl* 1997; 79: 58-68
41. Deland JT, Lee KT, Sobel M, et al. Anatomy of the plantar plate and its attachments in the lesser metatarsal phalangeal joint. *Foot Ankle Int* 1995; 16: 480-6
42. Manoli A, Weber TG. Fasciotomy of the foot: an anatomical study with special reference to release of the calcaneal compartment. *Foot Ankle* 1990; 10: 267-75
43. Martin BF. Observations on the muscles and tendons of the medial aspect of the sole of the foot. *J Anat* 1964; 98: 437-53
44. Boabighi A, Kuhlmann JN, Luboinski J, et al. Aponeuroses and superficial fascia: mechanical and structural properties [in French]. *Bull Assoc Anat (Nancy)* 1993; 77: 3-7
45. Wright DG, Rennels DC. A study of the elastic properties of plantar fascia. *J Bone Joint Surg Am* 1964; 46: 482-92
46. Amiel D, Frank C, Harwood F, et al. Tendons and ligaments: a morphological and biochemical comparison. *J Orthop Res* 1984; 1: 257-65
47. Davis WH, Sobel M, DiCarlo EF, et al. Gross, histological, and microvascular anatomy and biomechanical testing of the spring ligament complex. *Foot Ankle Int* 1996; 17: 95-102
48. Contri MB, Guerra D, Vignali N, et al. Ultrastructural and immunocytochemical study on normal human palmar aponeuroses. *Anat Rec* 1994; 240: 314-21
49. Waggett AD, Ralphs JR, Kwan AP, et al. Characterization of collagens and proteoglycans at the insertion of the human Achilles tendon. *Matrix Biol* 1998; 16: 457-70
50. Warren BL. Plantar fasciitis in runners: treatment and prevention. *Sports Med* 1990; 10: 338-45
51. McNeilly CM, Banes AJ, Benjamin M, et al. Tendon cells in vivo form a three dimensional network of cell processes linked by gap junctions. *J Anat* 1996; 189: 593-600
52. Ralphs JR, Benjamin M, Waggett AD, et al. Regional differences in cell shape and gap junction expression in rat Achilles tendon: relation to fibrocartilage differentiation. *J Anat* 1998; 193: 215-22
53. Benjamin M, Ralphs JR. The cell and developmental biology of tendons and ligaments. *Int Rev Cytol* 2000; 196: 85-130
54. Petrie S, Collins JG, Solomonow M, et al. Mechanoreceptors in the human elbow ligaments. *J Hand Surg [Am]* 1998; 23-A: 512-8
55. Zimny ML. Mechanoreceptors in articular tissues. *Am J Anat* 1988; 182: 16-32
56. Petrie S, Collins J, Solomonow M, et al. Mechanoreceptors in the palmar wrist ligaments. *J Bone Joint Surg Br* 1997; 79: 494-6
57. McDougall JJ, Bray RC, Sharkey KA. Morphological and immunohistochemical examination of nerves in normal and injured collateral ligaments of rat, rabbit, and human knee joints. *Anat Rec* 1997; 248: 29-39
58. Butler DL, Sheh MY, Stouffer DC, et al. Surface strain variation in human patellar tendon and knee cruciate ligaments. *J Biomech Eng* 1990; 112: 38-45
59. Noyes FR, Butler DL, Grood ES, et al. Biomechanical analysis of human ligament grafts used in knee-ligament repairs and reconstructions. *J Bone Joint Surg Am* 1984; 66: 344-52
60. Stouffer DC, Butler DL, Hosny D. The relationship between crimp pattern and mechanical response of human patellar tendon-bone units. *J Biomech Eng* 1985; 107: 158-65
61. Coggeshall RE, Hong KA, Langford LA, et al. Discharge characteristics of fine medial articular afferents at rest and during passive movements of inflamed knee joints. *Brain Res* 1983; 272: 185-8
62. Biedert RM, Stauffer E, Friederich NF. Occurrence of free nerve endings in the soft tissue of the knee joint: a histologic investigation. *Am J Sports Med* 1992; 20: 430-3
63. [Hogervorst T, Brand RA. Mechanoreceptors in joint function. J Bone Joint Surg Am 1998; 80: 1365-78](#)
64. Holzer P. Local effector functions of capsaicin-sensitive sensory nerve endings: involvement of tachykinins, calcitonin gene-related peptide and other neuropeptides. *Neuroscience* 1988; 24: 739-68
65. Salo PT, Theriault E. Number, distribution and neuropeptide content of rat knee joint afferents. *J Anat* 1997; 190: 515-22
66. Mosier SM, Lucas DR, Pomeroy G, et al. Pathology of the posterior tibial tendon in posterior tibial tendon insufficiency. *Foot Ankle Int* 1998; 19: 520-4
67. Benjamin M, Ralphs JR. Tendons and ligaments: an overview. *Histol Histopathol* 1997; 12: 1135-44
68. Ahmed IM, Lagopoulos M, McConnell P, et al. Blood supply of the Achilles tendon. *J Orthop Res* 1998; 16: 591-6
69. Frey C, Shereff M, Greenidge N. Vascularity of the posterior tibial tendon. *J Bone Joint Surg Am* 1990; 72: 884-8
70. Benjamin M, Ralphs JR. Fibrocartilage in tendons and ligaments: an adaptation to compressive load. *J Anat* 1998; 193: 481-94
71. Bray RC, Rangayyan RM, Frank CB. Normal and healing ligament vascularity: a quantitative histological assessment in the adult rabbit medial collateral ligament. *J Anat* 1996; 188: 87-95
72. [Petersen W, Hohmann G, Stein V, et al. The blood supply of the posterior tibial tendon. J Bone Joint Surg Br 2002; 84: 141-4](#)
73. Chowdhury P, Matyas JR, Frank CB. The 'epiligament' of the rabbit medial collateral ligament: a quantitative morphological study. *Connect Tissue Res* 1991; 27: 33-50
74. Åström M. Laser Doppler flowmetry in the assessment of tendon blood flow. *Scand J Med Sci Sports* 2000; 10: 365-7
75. Petersen W, Bobka T, Stein V, et al. Blood supply of the peroneal tendons: injection and immunohistochemical studies of cadaver tendons. *Acta Orthop Scand* 2000; 71: 168-74
76. Arnoczky SP, Rubin RM, Marshall JL. Microvasculature of the cruciate ligaments and its response to injury: an experimental study in dogs. *J Bone Joint Surg Am* 1979; 61: 1221-9
77. Benjamin M, Evans EJ, Copp L. The histology of tendon attachments to bone in man. *J Anat* 1986; 149: 89-100
78. Scapinelli R. Vascular anatomy of the human cruciate ligaments and surrounding structures. *Clin Anat* 1997; 10: 151-62
79. [Carr AJ, Norris SH. The blood supply of the calcaneal tendon. J Bone Joint Surg Br 1989; 71: 100-1](#)
80. [Petersen W, Tillmann B. Structure and vascularization of the cruciate ligaments of the human knee joint. Anat Embryol 1999; 200: 325-34](#)
81. Petersen W, Stein V, Bobka T. Structure of the human tibialis anterior tendon. *J Anat* 2000; 197: 617-25

82. Brooks CH, Revell WJ, Heatley FW. A quantitative histological study of the vascularity of the rotator cuff tendon. *J Bone Joint Surg Br* 1992; 74: 151-3
83. Geppert MJ, Sobel M, Hannafin JA. Microvasculature of the tibialis anterior tendon. *Foot Ankle* 1993; 14: 261-4
84. Schneeberger AG, Masquelet AC. Arterial vascularization of the proximal extensor carpi radialis brevis tendon. *Clin Orthop* 2002; 398: 239-44
85. Archambault JM, Wiley JP, Bray RC. Exercise loading of tendons and the development of overuse injuries: a review of current literature. *Sports Med* 1995; 20: 77-89
86. Theodorou DJ, Theodorou SJ, Farooki S, et al. Disorders of the plantar aponeurosis: a spectrum of MR imaging findings. *Am J Roentgenol* 2001; 176: 97-104
87. Woo S, Maynard J, Butler D, et al. Ligament, tendon, and joint capsule insertions to bone. In: Woo SL, Buckwalter JA, editors. *Injury and repair of the musculoskeletal soft tissues*. Park Ridge (IL): American Academy of Orthopedic Surgeons, 1987: 133-66
88. Benjamin M, McGonagle D. The anatomical basis for disease localisation in seronegative spondyloarthropathy at entheses and related sites. *J Anat* 2001; 199: 503-26
89. McGonagle D, Marzo-Ortega H, O'Connor P, et al. Histological assessment of the early enthesitis lesion in spondyloarthropathy. *Ann Rheum Dis* 2002; 61: 534-7
90. Cooper RR, Misol S. Tendon and ligament insertion: a light and electron microscopic study. *J Bone Joint Surg Am* 1970; 52: 1-20
91. Rufai A, Ralphs JR, Benjamin M. Structure and histopathology of the insertional region of the human Achilles tendon. *J Orthop Res* 1995; 13: 585-93
92. Merkel KH, Hess H, Kunz M. Insertion tendopathy in athletes: a light microscopic, histochemical and electron microscopic examination. *Pathol Res Pract* 1982; 173: 303-9
93. Rufai A, Ralphs JR, Benjamin M. Ultrastructure of fibrocartilages at the insertion of the rat Achilles tendon. *J Anat* 1996; 189: 185-91
94. Milz S, Rufai A, Buettner A, et al. Three-dimensional reconstructions of the Achilles tendon insertion in man. *J Anat* 2002; 200: 145-52
95. Gao J, Messner K. Quantitative comparison of soft tissue-bone interface at chondral ligament insertions in the rabbit knee joint. *J Anat* 1996; 188: 367-73
96. Evans EJ, Benjamin M, Pemberton DJ. Variations in the amount of calcified tissue at the attachments of the quadriceps tendon and patellar ligament in man. *J Anat* 1991; 174: 145-51
97. Benjamin M, Evans EJ, Rao RD, et al. Quantitative differences in the histology of the attachment zones of the meniscal horns in the knee joint of man. *J Anat* 1991; 177: 127-34
98. Gao J, Rasanen T, Persliden J, et al. The morphology of ligament insertions after failure at low strain velocity: an evaluation of ligament entheses in the rabbit knee. *J Anat* 1996; 189: 127-33
99. Benjamin M, Newell RL, Evans EJ, et al. The structure of the insertions of the tendons of biceps brachii, triceps and brachialis in elderly dissecting room cadavers. *J Anat* 1992; 180: 327-32
100. Mente PL, Lewis JL. Elastic modulus of calcified cartilage is an order of magnitude less than that of subchondral bone. *J Orthop Res* 1994; 12: 637-47
101. Shea JE, Hallows RK, Bloebaum RD. Experimental confirmation of the sheep model for studying the role of calcified fibrocartilage in hip fractures and tendon attachments. *Anat Rec* 2002; 266: 177-83
102. Vajda EG, Bloebaum RD. Age-related hypermineralization in the female proximal human femur. *Anat Rec* 1999; 255: 202-11
103. Boyde A, Jones SJ, Aerssens J, et al. Mineral density quantitation of the human cortical iliac crest by backscattered electron image analysis: variations with age, sex, and degree of osteoarthritis. *Bone* 1995; 16: 619-27
104. Matheson GO, MacIntyre JG, Taunton JE, et al. Musculoskeletal injuries associated with physical activity in older adults. *Med Sci Sports Exerc* 1989; 21: 379-85
105. Evans EJ, Benjamin M, Pemberton DJ. Fibrocartilage in the attachment zones of the quadriceps tendon and patellar ligament of man. *J Anat* 1990; 171: 155-62
106. Frowen P, Benjamin M. Variations in the quality of uncalcified fibrocartilage at the insertions of the extrinsic calf muscles in the foot. *J Anat* 1995; 186: 417-21
107. Milz S, Putz R, Ralphs JR, et al. Fibrocartilage in the extensor tendons of the human metacarpophalangeal joints. *Anat Rec* 1999; 256: 139-45
108. Benjamin M, Qin S, Ralphs JR. Fibrocartilage associated with human tendons and their pulleys. *J Anat* 1995; 187: 625-33
109. de Carvalho HF. Understanding the biomechanics of tendon fibrocartilages. *J Theor Biol* 1995; 172: 293-7
110. Kumai T, Takakura Y, Rufai A, et al. The functional anatomy of the human anterior talofibular ligament in relation to ankle sprains. *J Anat* 2002; 200: 457-65
111. Kitaoka HB, Luo ZP, Growney ES, et al. Material properties of the plantar aponeurosis. *Foot Ankle Int* 1994; 15: 557-60
112. Blevins FT, Hecker AT, Bigler GT, et al. The effects of donor age and strain rate on the biomechanical properties of bone-patellar tendon-bone allografts. *Am J Sports Med* 1994; 22: 328-33
113. Ker RF. Dynamic tensile properties of the plantaris tendon of sheep (*Ovis aries*). *J Exp Biol* 1981; 93: 283-302
114. Woo SLY, Peterson RH, Ohland KJ, et al. The effects of strain rate on the properties of the medial collateral ligament in skeletally immature and mature rabbits: a biomechanical and histological study. *J Orthop Res* 1990; 8: 712-21
115. Butler DL, Grood ES, Noyes FR, et al. On the interpretation of our anterior cruciate ligament data. *Clin Orthop* 1985; 196: 26-34
116. Johnson GA, Tramaglini DM, Levine RE, et al. Tensile and viscoelastic properties of human patellar tendon. *J Orthop Res* 1994; 12: 796-803
117. Noyes FR, DeLucas JL, Torvik PJ. Biomechanics of anterior cruciate ligament failure: an analysis of strain-rate sensitivity and mechanisms of failure in primates. *J Bone Joint Surg Am* 1974; 56: 236-53
118. Butler DL, Grood ES, Noyes FR, et al. Effects of structure and strain measurement technique on the material properties of young human tendons and fascia. *J Biomech* 1984; 17: 579-96

119. Wren TA, Yerby SA, Beaupré GS, et al. Mechanical properties of the human Achilles tendon. *Clin Biomech* 2001; 16: 245-51
120. Danto MI, Woo SL. The mechanical properties of skeletally mature rabbit anterior cruciate ligament and patellar tendon over a range of strain rates. *J Orthop Res* 1993; 11: 58-67
121. Wren TA, Yerby SA, Beaupre GS, et al. Influence of bone mineral density, age, and strain rate on the failure mode of human Achilles tendons. *Clin Biomech* 2001; 16: 529-34
122. Ambrose CG, Kiezbak GM, Sabonghy EP, et al. Biomechanical testing of cadaveric specimens: importance of bone mineral density assessment. *Foot Ankle Int* 2002; 23: 850-5
123. Woo SLY, Hollis JM, Adams DJ, et al. Tensile properties of the human femur-anterior cruciate ligament-tibia complex: the effects of specimen age and orientation. *Am J Sports Med* 1991; 19: 217-25
124. [Haut Donahue TL, Gregersen C, Hull ML, et al. Comparison of viscoelastic, structural, and material properties of double-looped anterior cruciate ligament grafts made from bovine digital extensor and human hamstring tendons. \*J Biomech Eng\* 2001; 123: 162-9](#)
125. Lewis G, Shaw KM. Tensile properties of human tendo achillis: effect of donor age and strain rate. *J Foot Ankle Surg* 1997; 36: 435-45
126. Attarian DE, McCrackin HJ, DeVito DP, et al. Biomechanical characteristics of human ankle ligaments. *Foot Ankle* 1985; 6: 54-8
127. Harner CD, Xerogeanes JW, Livesay GA, et al. The human posterior cruciate ligament complex: an interdisciplinary study: ligament morphology and biomechanical evaluation. *Am J Sports Med* 1995; 23: 736-45
128. Momersteeg TJ, Blankevoort L, Huijskes R, et al. The effect of variable relative insertion orientation of human knee bone-ligament-bone complexes on the tensile stiffness. *J Biomech* 1995; 28: 745-52
129. Przybylski GJ, Carlin GJ, Patel PR, et al. Human anterior and posterior cervical longitudinal ligaments possess similar tensile properties. *J Orthop Res* 1996; 14: 1005-8
130. Race A, Amis AA. The mechanical properties of the two bundles of the human posterior cruciate ligament. *J Biomech* 1994; 27: 13-24
131. Siegler S, Block J, Schneck CD. The mechanical characteristics of the collateral ligaments of the human ankle joint. *Foot Ankle* 1988; 8: 234-42
132. Hinton R, Jinnah RH, Johnson C, et al. A biomechanical analysis of solvent-dehydrated and freeze-dried human fascia lata allografts: a preliminary report. *Am J Sports Med* 1992; 20: 607-12
133. Parry DA. The molecular and fibrillar structure of collagen and its relationship to the mechanical properties of connective tissue. *Biophys Chem* 1988; 29: 195-209
134. Strocchi R, de Pasquale V, Gubellini P, et al. The human anterior cruciate ligament: histological and ultrastructural observations. *J Anat* 1992; 180: 515-9
135. [Hurschler C, Vanderby R, Martinez DA, et al. Mechanical and biochemical analyses of tibial compartment fascia in chronic compartment syndrome. \*Ann Biomed Eng\* 1994; 22: 272-9](#)
136. Kura H, Luo ZP, Kitaoka HB, et al. Mechanical behavior of the Lisfranc and dorsal cuneometatarsal ligaments: in vitro biomechanical study. *J Orthop Trauma* 2001; 15: 107-10
137. Bennett MB, Ker RF, Dimery NJ, et al. Mechanical properties of various mammalian tendons. *J Zool* 1986; 209: 537-48
138. Iaconis F, Steindler R, Marinozzi G. Measurements of cross-sectional area of collagen structures (knee ligaments) by means of an optical method. *J Biomech* 1987; 20: 1003-10
139. Race A, Amis AA. Cross-sectional area measurement of soft tissue: a new casting method. *J Biomech* 1996; 29: 1207-12
140. Woo SL, Danto MI, Ohland KJ, et al. The use of a laser micrometer system to determine the cross-sectional shape and area of ligaments: a comparative study with two existing methods. *J Biomech Eng* 1990; 112: 426-31
141. Benedict JV, Walker LB, Harris EH. Stress-strain characteristics and tensile strength of unembalmed human tendon. *J Biomech* 1968; 1: 53-63
142. [Butler DL, Kay MD, Stouffer DC. Comparison of material properties in fascicle-bone units from human patellar tendon and knee ligaments. \*J Biomech\* 1986; 19: 425-32](#)
143. Itoi E, Berglund LJ, Grabowski JJ, et al. Tensile properties of the supraspinatus tendon. *J Orthop Res* 1995; 13: 578-84
144. Stäubli HU, Schatzmann L, Brunner P, et al. Mechanical tensile properties of the quadriceps tendon and patellar ligament in young adults. *Am J Sports Med* 1999; 27: 27-34
145. Butler DL, Guan Y, Kay MD, et al. Location-dependent variations in the material properties of the anterior cruciate ligament. *J Biomech* 1992; 25: 511-8
146. Quapp KM, Weiss JA. Material characterization of human medial collateral ligament. *J Biomech Eng* 1998; 120: 757-63
147. Kubo K, Kawakami Y, Kanehisa H, et al. Measurement of viscoelastic properties of tendon structures in vivo. *Scand J Med Sci Sports* 2002; 12: 3-8
148. Haut RC, Powlison AC. The effects of test environment and cyclic stretching on the failure properties of human patellar tendons. *J Orthop Res* 1990; 8: 532-40
149. Haut TL, Haut RC. The state of tissue hydration determines the strain-rate-sensitive stiffness of human patellar tendon. *J Biomech* 1997; 30: 79-81
150. [Thornton GM, Shrive NG, Frank CB. Altering ligament water content affects ligament pre-stress and creep behaviour. \*J Orthop Res\* 2001; 19: 845-51](#)
151. Flahiff CM, Brooks AT, Hollis JM, et al. Biomechanical analysis of patellar tendon allografts as a function of donor age. *Am J Sports Med* 1995; 23: 354-8
152. Haut RC, Lancaster RL, DeCamp CE. Mechanical properties of the canine patellar tendon: some correlations with age and the content of collagen. *J Biomech* 1992; 25: 163-73
153. Hubbard RP, Soutas-Little RW. Mechanical properties of human tendon and their age dependence. *J Biomech Eng* 1984; 106: 144-50
154. Lee TQ, Dettling J, Sandusky MD, et al. Age related biomechanical properties of the glenoid-anterior band of the inferior glenohumeral ligament-humerus complex. *Clin Biomech* 1999; 14: 471-6
155. Tuite DJ, Renstrom PA, O'Brien M. The aging tendon. *Scand J Med Sci Sports* 1997; 7: 72-7



156. Kirkendall DT, Garrett WE. Function and biomechanics of tendons. *Scand J Med Sci Sports* 1997; 7: 62-6
157. Maganaris CN, Narici MV, Almekinders LC, et al. Biomechanics and pathophysiology of overuse tendon injuries: ideas on insertional tendinopathy. *Sports Med* 2004; 34: 1005-17
158. Vasseur PB, Pool RR, Arnoczky SP, et al. Correlative biomechanical and histologic study of the cranial cruciate ligament in dogs. *Am J Vet Res* 1985; 46: 1842-54
159. Sano H, Ishii H, Yeadon A, et al. Degeneration at the insertion weakens the tensile strength of the supraspinatus tendon: a comparative mechanical and histologic study of the bone-tendon complex. *J Orthop Res* 1997; 15: 719-26
160. Soslowky LJ, Thomopoulos S, Tun S, et al. Overuse activity injures the supraspinatus tendon in an animal model: a histologic and biomechanical study. *J Shoulder Elbow Surg* 2000; 9: 79-84
161. Kannus P, Józsa L. Histopathological changes preceding spontaneous rupture of a tendon: a controlled study of 891 patients. *J Bone Joint Surg Am* 1991; 73: 1507-25
162. Ker RF, Bennett MB, Bibby SR, et al. The spring in the arch of the human foot. *Nature* 1987; 325: 147-9
163. [Murphy GA, Pneumatics SG, Kamaric E, et al. Biomechanical consequences of sequential plantar fascia release. \*Foot Ankle Int\* 1998; 19: 149-52](#)
164. [Kitaoka HB, Luo ZP, An KN. Mechanical behavior of the foot and ankle after plantar fascia release in the unstable foot. \*Foot Ankle Int\* 1997; 18: 8-15](#)
165. Thordarson DB, Hedman T, Lundquist D, et al. Effect of calcaneal osteotomy and plantar fasciotomy on arch configuration in a flatfoot model. *Foot Ankle Int* 1998; 19: 374-8
166. Kitaoka HB, Luo ZP, An KN. Effect of plantar fasciotomy on stability of arch of foot. *Clin Orthop* 1997; 344: 307-12
167. Kitaoka HB, Ahn TK, Luo ZP, et al. Stability of the arch of the foot. *Foot Ankle Int* 1997; 18: 644-8
168. [Anderson DJ, Fallat LM, Savoy-Moore RT. Computer-assisted assessment of lateral column movement following plantar fascial release: a cadaveric study. \*J Foot Ankle Surg\* 2001; 40: 62-70](#)
169. Hicks JH. The foot as a support. *Acta Anat* 1955; 25: 34-45
170. Sarrafian SK. Functional characteristics of the foot and plantar aponeurosis under tibiotalar loading. *Foot Ankle* 1987; 8: 4-18
171. Vogler HW, Bojsen-Moller F. Tarsal functions, movement, and stabilization mechanisms in foot, ankle and leg performance. *J Am Podiatr Med Assoc* 2000; 90: 112-25
172. Kogler GF, Solomonidis SE, Paul JP. In vitro method for quantifying the effectiveness of the longitudinal arch support mechanism of a foot orthosis. *Clin Biomech* 1995; 10: 245-52
173. Kogler GF, Solomonidis SE, Paul JP. Biomechanics of longitudinal arch support mechanisms in foot orthoses and their effect on plantar aponeurosis strain. *Clin Biomech* 1996; 11: 243-52
174. Kogler GF, Veer FB, Solomonidis SE, et al. The influence of medial and lateral placement of orthotic wedges on loading of the plantar aponeurosis. *J Bone Joint Surg Am* 1999; 81: 1403-13
175. Huang CK, Kitaoka HB, An KN, et al. Biomechanical stability of the arch. *Foot Ankle* 1993; 14: 353-7
176. Arangio GA, Salathe EP. Medial displacement calcaneal osteotomy reduces the excess forces in the medial longitudinal arch of the flat foot. *Clin Biomech* 2001; 16: 535-9
177. Arangio GA, Chen C, Salathe EP. Effect of varying arch height with and without the plantar fascia on the mechanical properties of the foot. *Foot Ankle Int* 1998; 19: 705-9
178. Gefen A. Stress analysis of the standing foot following surgical plantar fascia release. *J Biomech* 2002; 35: 629-37
179. Arangio GA, Chen C, Kim W. Effect of cutting the plantar fascia on mechanical properties of the foot. *Clin Orthop* 1997; 339: 227-31
180. Kim W, Voloshin AS. Role of the plantar fascia in the load bearing capacity of the human foot. *J Biomech* 1995; 28: 1025-33
181. Carlsoo S, Wetzstein H. Change of form of the foot and the foot skeleton upon momentary weight-bearing. *Acta Orthop Scand* 1968; 39: 413-23
182. Salathe EP, Arangio GA, Salathe EP. A biomechanical model of the foot. *J Biomech* 1986; 19: 989-1001
183. Williams A, Vedi V, Singh D, et al. Hick's revisited: a weightbearing in vivo study of the biomechanics of the plantar fascia employing dynamic M.R.I. *J Bone Joint Surg Br* 1999; 81: 381
184. [Vedi V, Williams A, Singh D, et al. Hick's revisited: a weightbearing in vivo study of the biomechanics of the plantar fascia employing 'dynamic' MRI \[abstract\]. \*J Bone Joint Surg Br\* 1999; 81: 156](#)
185. Hicks JH. The mechanics of the foot: the plantar aponeurosis and the arch. *J Anat* 1954; 88: 25-30
186. Rush SM, Christensen JC, Johnson CH. Biomechanics of the first ray, part 2: metatarsus primus varus as a cause of hypermobility – a three dimensional kinematic analysis in a cadaver model. *J Foot Ankle Surg* 2000; 39: 68-75
187. Bojsen-Moller F. Calcaneocuboid joint and stability of the longitudinal arch of the foot at high and low gear push off. *J Anat* 1979; 129: 165-76
188. Hicks JH. The mechanics of the foot: the joints. *J Anat* 1953; 87: 345-57
189. [Thordarson DB, Schmotzer H, Chon J, et al. Dynamic support of the human longitudinal arch: a biomechanical evaluation. \*Clin Orthop\* 1995; 316: 165-72](#)
190. Kappel-Bargas A, Woolf RD, Cornwall MW, et al. The windlass mechanism during normal walking and passive first metatarsalphalangeal joint extension. *Clin Biomech* 1998; 13: 190-4
191. Hetherington VJ, Carnett J, Patterson BA. Motion of the first metatarsalphalangeal joint. *J Foot Surg* 1989; 28: 13-9
192. Shereff MJ, Bejjani FJ, Kummer FJ. Kinematics of the first metatarsalphalangeal joint. *J Bone Joint Surg Am* 1986; 68: 392-8
193. [Kogler GF, Veer FB, Verhulst SJ, et al. The effect of heel elevation on strain within the plantar aponeurosis: in vitro study. \*Foot Ankle Int\* 2001; 22: 433-9](#)
194. Winson IG, Lundberg A, Bylund C. The pattern of motion of the longitudinal arch. *Foot* 1994; 4: 151-4
195. Sharkey NA, Ferris L, Donahue SW. Biomechanical consequences of plantar fascial release or rupture during gait, part I:

- disruptions in longitudinal arch conformation. *Foot Ankle Int* 1998; 19: 812-20
196. Carlson RE, Fleming LL, Hutton WC. The biomechanical relationship between the tendoachilles, plantar fascia and metatarsophalangeal joint dorsiflexion angle. *Foot Ankle Int* 2000; 21: 18-25
  197. Kitaoka HB, Luo ZP, An KN. Effect of the posterior tibial tendon on the arch of the foot during simulated weightbearing: biomechanical analysis. *Foot Ankle Int* 1997; 18: 43-6
  198. Donn AW, Nicol AC. Ligament strain measurements in cadaveric feet during simulated functional activities. In: Hakkinen K, editor. 15th Congress of the International Society of Biomechanics; 1995 Jul 2-6; Jyväskylä, Finland: 1995: 226-7
  199. Hamel AJ, Donahue SW, Sharkey NA. Contributions of active and passive toe flexion to forefoot loading. *Clin Orthop* 2001; 393: 326-34
  200. Tansey PA, Briggs PJ. Active and passive mechanisms in the control of heel supination. *J Foot Ankle Surg* 2001; 7: 131-6
  201. Salathe EP, Arangio GP. A biomechanical model of the foot: the role of muscles, tendons, and ligaments. *J Biomech Eng* 2002; 124: 281-7
  202. Duranti R, Galletti R, Pantaleo T. Electromyographic observations in patients with foot pain syndromes. *Am J Phys Med* 1985; 64: 295-304
  203. Basmajian JV, Stecko G. The role of muscles in arch support of the foot: an electromyographic study. *J Bone Joint Surg Am* 1963; 45: 1184-90
  204. Reeser LA, Susman RL, Stern JT. Electromyographic studies of the human foot: experimental approaches to hominid evolution. *Foot Ankle* 1983; 3: 391-407
  205. Mann R, Inman VT. Phasic activity of intrinsic muscles of the foot. *J Bone Joint Surg Am* 1964; 46: 469-81
  206. Kayano J. Dynamic function of medial foot arch. *Nippon Seikeigeka Gakkai Zasshi* 1986; 60: 1147-56
  207. Sharkey NA, Donahue SW, Ferris L. Biomechanical consequences of plantar fascial release or rupture during gait, part II: alterations in forefoot loading. *Foot Ankle Int* 1999; 20: 86-96
  208. Harton FM, Weiskopf SA, Goecker RM. Sectioning the plantar fascia: effect on first metatarsophalangeal joint motion. *J Am Podiatr Med Assoc* 2002; 92: 532-6
  209. Pardiwala A, Henry APJ. Traumatic rupture of the plantar fascia leading to development of claw toe deformity: two case reports. *J Foot Ankle Surg* 2001; 7: 197-200
  210. Mann R, Poppen NK, O'Konski M. Amputation of the great toe: a clinical and biomechanical study. *Clin Orthop* 1988; 226: 192-205
  211. Wearing SC, Urry SR, Smeathers JE. Ground reaction forces at discrete sites of the foot derived from pressure plate measurements. *Foot Ankle Int* 2001; 22: 653-61
  212. Hughes J, Clark P, Klenerman L. The importance of the toes in walking. *J Bone Joint Surg Br* 1990; 72: 245-51
  213. Cornwall MW, McPoil TG. Motion of the calcaneus, navicular, and first metatarsal during the stance phase of walking. *J Am Podiatr Med Assoc* 2002; 92: 67-76
  214. Scott SH, Winter DA. Biomechanical model of the human foot: kinematics and kinetics during the stance phase of walking. *J Biomech* 1993; 26: 1091-104
  215. Leardini A, Benedetti MG, Catani F, et al. An anatomically based protocol for the description of foot segment kinematics during gait. *Clin Biomech* 1999; 14: 528-36
  216. Wearing SC, Urry S, Perlman P, et al. Sagittal plane motion of the human arch during gait: a videofluoroscopic analysis. *Foot Ankle Int* 1998; 19: 738-42
  217. Yang SM, Kayamo J, Norimatsu T, et al. Dynamic changes of the arches of the foot during walking. In: Winter DA, Norman RW, Wells RP, et al., editors. *Biomechanics IX: international series on biomechanics*. Champaign (IL): Human Kinetics, 1985: 417-22
  218. Wearing SC, Smeathers JE, Yates B, et al. Sagittal movement of the medial longitudinal arch is unchanged in plantar fasciitis. *Med Sci Sports Exerc* 2004; 36: 1761-7
  219. Hunt AE, Smith RM, Torode M. Extrinsic muscle activity, foot motion and ankle joint moments during the stance phase of walking. *Foot Ankle Int* 2001; 22: 31-41
  220. Hunt AE, Smith RM, Torode M, et al. Inter-segment foot motion and ground reaction forces over the stance phase of walking. *Clin Biomech* 2001; 16: 592-600
  221. Cashmere T, Smith R, Hunt A. Medial longitudinal arch of the foot: stationary versus walking measures. *Foot Ankle Int* 1999; 20: 112-8
  222. Phillips RD, Law EA, Ward ED. Functional motion of the medial column joints of the foot during propulsion. *J Am Podiatr Med Assoc* 1996; 86: 474-86
  223. Kameyama O, Ogawa R, Okamoto T, et al. Electric discharge patterns of ankle muscles during the normal gait cycle. *Arch Phys Med Rehabil* 1990; 71: 969-74
  224. Blanc Y, Balmer C, Landis T, et al. Temporal parameters and patterns of the foot roll over during walking: normative data for healthy adults. *Gait Posture* 1999; 10: 97-108
  225. Sutherland DH, Kaufman KR, Moitoza JR. Kinematics of normal human walking. In: Rose J, Gamble JG, editors. *Human walking*. Sydney: Williams & Wilkins, 1994: 23-44
  226. Andriacchi TP, Alexander EJ. Studies of human locomotion: past, present and future. *J Biomech* 2000; 33: 1217-24
  227. Maslen BA, Ackland TR. Radiographic study of the skin displacement errors in the foot and ankle during standing. *Clin Biomech* 1994; 9: 291-6
  228. Giddings VL, Beaupre GS, Whalen RT, et al. Calcaneal loading during walking and running. *Med Sci Sports Exerc* 2000; 32: 627-34
  229. Scott SH, Winter DA. Internal forces of chronic running injury sites. *Med Sci Sports Exerc* 1990; 22: 357-69
  230. Gefen A. The in vivo elastic properties of the plantar fascia during the contact phase of walking. *Foot Ankle Int* 2003; 24: 238-44
  231. Maganaris CN, Paul JP. In vivo human tendon mechanical properties. *J Physiol* 1999; 521: 307-13
  232. Magnusson SP, Aagaard P, Dyhre-Poulsen P, et al. Load-displacement properties of the human triceps surae aponeurosis in vivo. *J Physiol* 2001; 531: 277-88
  233. Muramatsu T, Muraoka T, Takeshita D, et al. Mechanical properties of tendon and aponeurosis of human gastrocnemius muscle in vivo. *J Appl Physiol* 2001; 90: 1671-8
  234. Rosager S, Aagaard P, Dyhre-Poulsen P, et al. Load-displacement properties of the human triceps surae aponeurosis and



- tendon in runners and non-runners. *Scand J Med Sci Sports* 2002; 12: 90-8
235. Erdemir A, Hamel AJ, Fauth AR, et al. Dynamic loading of the plantar aponeurosis in walking. *J Bone Joint Surg Am* 2004; 86: 546-52
  236. Malaviya P, Butler DL, Korvick DL, et al. In vivo tendon forces correlate with activity level and remain bounded: evidence in a rabbit flexor tendon model. *J Biomech* 1998; 31: 1043-9
  237. Grasel RP, Schweitzer ME, Kovalovich AM, et al. MR imaging of plantar fasciitis: edema, tears, and occult marrow abnormalities correlated with outcome. *Am J Roentgenol* 1999; 173: 699-701
  238. Schepsis AA, Leach RE, Gorzyca J. Plantar fasciitis: etiology, treatment, surgical results, and review of the literature. *Clin Orthop* 1991; 266: 185-96
  239. Snider MP, Clancy WG, McBeath AA. Plantar fascia release for chronic plantar fasciitis in runners. *Am J Sports Med* 1983; 11: 215-9
  240. LeMelle DP, Kisilewicz P, Janis LR. Chronic plantar fascial inflammation and fibrosis. *Clin Podiatr Med Surg* 1990; 7: 385-9
  241. Clancy Jr WG. Tendinitis and plantar fasciitis in runners. *Orthop* 1983; 6: 217-33
  242. Józsa LG, Kannus P. Human tendons: anatomy, physiology and pathology. Champaign (IL): Human Kinetics, 1997
  243. Chard MD, Cawston TE, Riley GP, et al. Rotator cuff degeneration and lateral epicondylitis: a comparative histological study. *Ann Rheum Dis* 1994; 53: 30-4
  244. Åström M, Rausing A. Chronic Achilles tendinopathy: a survey of surgical and histopathologic findings. *Clin Orthop* 1995; 316: 151-64
  245. Leach RF, Seavey MS, Salter DK. Results of surgery in athletes with plantar fasciitis. *Foot Ankle* 1986; 7: 156-61
  246. Lemont H, Ammirati KM, Usen N. Plantar fasciitis: a degenerative process (fasciosis) without inflammation. *J Am Podiatr Med Assoc* 2003; 93: 234-7
  247. Kumagai J, Sarkar K, Uthoff HK. The collagen types in the attachment zone of rotator cuff tendons in the elderly: an immunohistochemical study. *J Rheumatol* 1994; 21: 2096-100
  248. Kumai T, Benjamin M. Heel spur formation and the subcalcaneal entheses of the plantar fascia. *J Rheumatol* 2002; 29: 1957-64
  249. Ogata S, Uthoff HK. Acromioclavicular enthesopathy and rotator cuff tear: a radiologic and histologic postmortem investigation of the coracoacromial arch. *Clin Orthop* 1990; 254: 39-48
  250. Abreu MR, Chung CB, Mendes L, et al. Plantar calcaneal enthesophytes: new observations regarding sites of origin based on radiographic, MR imaging, anatomic, and paleopathologic analysis. *Skeletal Radiol* 2003; 32: 13-21
  251. Skedros JG, Bloebaum RD, Mason MW, et al. Analysis of a tension/compression skeletal system: possible strain-specific differences in the hierarchical organization of bone. *Anat Rec* 1994; 239: 396-404
  252. Wainwright AM, Kelly AJ, Winson G. Calcaneal spurs and plantar fasciitis. *Foot* 1995; 5: 123-6
  253. Shaibani A, Workman R, Rothschild BM. The significance of enthesopathy as a skeletal phenomenon. *Clin Exp Rheumatol* 1993; 11: 399-403
  254. Khan KM, Cook JL, Taunton JE, et al. Overuse tendinosis, not tendinitis: part 1: a new paradigm for a difficult clinical problem. *Phys Sportsmed* 2000; 28: 38-48
  255. Maffulli N, Khan KM, Puddu G. Overuse tendon conditions: time to change a confusing terminology. *Arthroscopy* 1998; 14: 840-3
  256. Almekinders LC, Temple JD. Etiology, diagnosis, and treatment of tendonitis: an analysis of the literature. *Med Sci Sports Exerc* 1998; 30: 1183-90
  257. Mosier SM, Pomeroy G, Manoli A. Pathoanatomy and etiology of posterior tibial tendon dysfunction. *Clin Orthop* 1999; 365: 12-22
  258. Hess GP, Cappiello WL, Poole RM, et al. Prevention and treatment of overuse tendon injuries. *Sports Med* 1989; 8: 371-84
  259. Backman C, Boquist L, Fridén J, et al. Chronic achilles paratenonitis with tendinosis: an experimental model in the rabbit. *J Orthop Res* 1990; 8: 541-7
  260. Enwemeka CS. Inflammation, cellularity, and fibrillogenesis in regenerating tendon: implications for tendon rehabilitation. *Phys Ther* 1989; 69: 816-25
  261. Herrick RT, Herrick S. Rupture of the plantar fascia in a middle-aged tennis player: a case report. *Am J Sports Med* 1983; 11: 95
  262. Lun V, Meeuwisse W, Vellet D. Spontaneous rupture of plantar fascia. *Clin J Sport Med* 1999; 9: 48-9
  263. Rolf C, Guntner P, Ericsson J, et al. Plantar fascia rupture: diagnosis and treatment. *J Foot Ankle Surg* 1997; 36: 112-4
  264. Józsa L, Réffy A, Kannus P, et al. Pathological alterations in human tendons. *Arch Orthop Trauma Surg* 1990; 110: 15-21
  265. Kannus P, Natri A. Etiology and pathophysiology of tendon ruptures in sports. *Scand J Med Sci Sports* 1997; 7: 107-12
  266. Carpenter JE, Flanagan CL, Thomopoulos S, et al. The effects of overuse combined with intrinsic or extrinsic alterations in an animal model of rotator cuff tendinosis. *Am J Sports Med* 1998; 26: 801-7
  267. Archambault JM, Herzog W, Hart DA. Acute and chronic tendon overuse in a rabbit model. 23rd Annual Meeting of the American Society of Biomechanics; 1999 Oct 21-23; Pittsburgh (PA)
  268. Kannus P. Etiology and pathophysiology of chronic tendon disorders in sports. *Scand J Med Sci Sports* 1997; 7: 78-85
  269. Kraus-Hansen AE, Fackelman GE, Becker C, et al. Preliminary studies on the vascular anatomy of the equine superficial digital flexor tendon. *Equine Vet J* 1992; 24: 46-51
  270. Wilson AM, Goodship AE. Exercise-induced hyperthermia as a possible mechanism for tendon degeneration. *J Biomech* 1994; 27: 899-905
  271. Józsa L, Kvist M, Balint BJ, et al. The role of recreational sport activity in Achilles tendon rupture: a clinical, pathoanatomical, and sociological study of 292 cases. *Am J Sports Med* 1989; 17: 338-43
  272. Józsa L, Balint JB, Kannus P, et al. Distribution of blood groups in patients with tendon rupture: an analysis of 832 cases. *J Bone Joint Surg Br* 1989; 71: 272-4
  273. Kujala UM, Jarvinen M, Natri A, et al. ABO blood groups and musculoskeletal injuries. *Injury* 1992; 23: 131-3

274. Maffulli N, Reaper JA, Waterston SW, et al. ABO blood groups and achilles tendon rupture in the Grampian Region of Scotland. *Clin J Sport Med* 2000; 10: 269-71
275. Leppilahti J, Puranen J, Orava S. ABO blood group and Achilles tendon rupture. *Ann Chir Gynaecol* 1996; 85: 369-71
276. Chandler TJ, Kibler WB. A biomechanical approach to the prevention, treatment, and rehabilitation of plantar fasciitis. *Sports Med* 1993; 15: 344-52
277. Cornwall MW, McPoil TG. Plantar fasciitis: etiology and treatment. *J Orthop Sports Phys Ther* 1999; 29: 756-60
278. Murphy DF, Connolly DAJ, Beynonn BD. Risk factors for lower extremity injury: a review of the literature. *Br J Sports Med* 2002; 37: 13-29
279. James SL, Bates BT, Osternig LR. Injuries to runners. *Am J Sports Med* 1978; 6: 40-50
280. Taunton JE, Clement DB, McNicol K. Plantar fasciitis in runners. *Can J Appl Sport Sci* 1982; 7: 41-4
281. Kibler WB, Goldberg C, Chandler J. Functional biomechanical deficits in running athletes with plantar fasciitis. *Am J Sports Med* 1991; 19: 66-71
282. Warren BL. Anatomical factors associated with predicting plantar fasciitis in long-distance runners. *Med Sci Sports Exerc* 1984; 16: 60-3
283. Warren BL, Jones CJ. Predicting plantar fasciitis in runners. *Med Sci Sports Exerc* 1987; 19: 71-3
284. Messier SP, Pittala KA. Etiologic factors associated with select running injuries. *Med Sci Sports Exerc* 1988; 20: 501-5
285. Hill JJ, Cutting PJ. Heel pain and body weight. *Foot Ankle* 1989; 9: 254-6
286. Prichasuk S. The heel pad in plantar heel pain. *J Bone Joint Surg Br* 1994; 76: 140-2
287. Turgut A, Gokturk E, Kose N, et al. The relationship of heel pad elasticity and plantar heel pain. *Clin Orthop* 1999; 360: 191-6
288. Tsai WC, Wang CL, Hsu TC, et al. The mechanical properties of the heel pad in unilateral plantar heel pain syndrome. *Foot Ankle Int* 1999; 20: 663-8
289. Wilk BR, Fisher KL, Gutierrez W. Defective running shoes as a contributing factor in plantar fasciitis in a triathlete. *J Orthop Sports Phys Ther* 2000; 30: 21-8
290. Rano JA, Fallet LM, Savoy-Moore RT. Correlation of heel pain with body mass index and other characteristics of heel pain. *J Foot Ankle Surg* 2001; 40: 351-6
291. Rome K, Campbell R, Flint A, et al. Heel pad thickness: a contributing factor associated with plantar heel pain in young adults. *Foot Ankle Int* 2002; 23: 142-74
292. Whittle MW. Generation and attenuation of transient impulsive forces beneath the foot: a review. *Gait Posture* 1999; 10: 264-75
293. Spears IR, Miller-Young JE, Waters M, et al. The effect of loading conditions on stress in the barefooted heel pad. *Med Sci Sports Exerc* 2005; 37: 1030-6
294. Liddle D, Rome K, Howe T. Vertical ground reaction forces in patients with unilateral plantar heel pain: a pilot study. *Gait Posture* 2000; 11: 62-6
295. Katoh Y, Chao EYS, Laughman RK, et al. Biomechanical analysis of foot function during gait and clinical applications. *Clin Orthop* 1983; 177: 23-33
296. Katoh Y, Chao EYS, Morrey BF, et al. Objective technique for evaluating painful heel syndrome and its treatment. *Foot Ankle* 1983; 3: 227-37
297. Daly PJ, Kitaoka HB, Chao EYS. Plantar fasciotomy for intractable plantar fasciitis: clinical results and biomechanical evaluation. *Foot Ankle* 1992; 13: 188-95
298. Wearing SC, Smeathers JE, Urry SR. The effect of plantar fasciitis on vertical foot-ground reaction force. *Clin Orthop* 2003; 409: 175-85
299. Katoh Y, Chao EYS, Morrey BF, et al. Objective evaluation of painful heel syndrome by gait analysis. In: Matsui H, Kobayashi K, editors. *Biomechanics VIII: proceedings of the 8th International Congress of Biomechanics*. Champaign (IL): Human Kinetics, 1981: 490-7
300. Kelly AJ, Wainwright AM, Winson IG. Plantar pressures are normal in plantar fasciitis. *Foot Dis* 1995; 11: 129-32
301. Bedi HS, Love BRT. Differences in impulse distribution patterns in patients with plantar fasciitis. *Foot Ankle Int* 1998; 19: 153-6
302. Kanatli U, Yetkin H, Simsek A, et al. The relationship of the heel pad compressibility and plantar pressure distribution. *Foot Ankle Int* 2001; 22: 662-5
303. Kwong PK, Kay D, Voner RT, et al. Plantar fasciitis: mechanics and pathomechanics of treatment. *Clin Sports Med* 1988; 7: 119-26
304. Huang YC, Wang LY, Wang HC, et al. The relationship between the flexible flatfoot and plantar fasciitis: ultrasonographic evaluation. *Chang Gung Med J* 2004; 27: 443-8
305. Kosmahl EM, Kosmahl HE. Painful plantar heel, plantar fasciitis and calcaneal spur: etiology and treatment. *J Orthop Sports Phys Ther* 1987; 9: 17-24
306. Ross M. Use of the tissue stress model as a paradigm for developing an examination and management plan for a patient with plantar fasciitis. *J Am Podiatr Med Assoc* 2002; 92: 499-506
307. Prichasuk S, Subhadrabandhu T. The relationship of pes planus and calcaneal spur to plantar heel pain. *Clin Orthop* 1994; 306: 192-6
308. Shama SS, Kominsky SJ, Lemont H. Prevalence of non painful heel spur and its relation to postural foot position. *J Am Podiatry Assoc* 1983; 73: 122-3
309. Lyman J, Weinhold PS, Almekinders LC. Strain behavior of the distal achilles tendon: implications for insertional achilles tendinopathy. *Am J Sports Med* 2004; 32: 457-61
310. Almekinders LC, Vellema JH, Weinhold PS. Strain patterns in the patellar tendon and the implications for patellar tendinopathy. *Knee Surg Sports Traumatol Arthrosc* 2002; 10: 2-5
311. Almekinders LC, Weinhold PS, Maffulli N. Compression etiology in tendinopathy. *Clin Sports Med* 2003; 22: 703-10

---

Correspondence and offprints: Dr *Scott C. Wearing*, Centre of Excellence for Applied Sports Science Research, Queensland Academy of Sport, PO Box 956, Sunnybank, QLD 4109, Australia.  
E-mail: [s.wearing@qut.edu.au](mailto:s.wearing@qut.edu.au)

Copyright of *Sports Medicine* is the property of ADIS International Limited and its content may not be copied or emailed to multiple sites or posted to a listserv without the copyright holder's express written permission. However, users may print, download, or email articles for individual use.