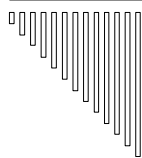


Acute cordecompensatie en acuut longoedeem

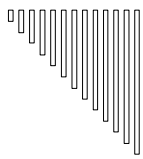
**Brevet Acute Geneeskunde
Academiejaar 2007-2008**

**Prof. dr. P. Calle,
Universitair Ziekenhuis Gent**



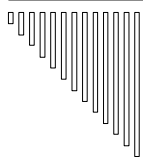
Acute cordecompensatie en acuut longoedeem

1. Acuut linker hartfalen (acuut longoedeem)
 2. Acuut rechter hartfalen
 3. Cardiogene shock
-



Acuut longoedeem

- (1. Anamnese)
 2. Klinisch beeld
 - (3. Etiologie)
 4. Differentiaal diagnose
 - (5. Technische investigaties)
 6. Therapie
 7. Prognose
-



Symptomen

- Dyspneu
 - Orthopneu
 - Tachypneu (cave bradypneu)
 - Expectoratie van rozig schuim
 - Profuus zweten, klamme huid, grauwe kleur
-



Klinisch onderzoek

- Gebruik van accessoire ademhalingspiers
- Luidruchtig inspirium, gorgelend expirium
- Grote ronchi, vnl. t.h.v. longbasis
(cave: wheezing door reflex bronchospasmen)
- [3^{de} harttoon, klepperuizen]
- Hypertensie - normotensie - hypotensie
- Tachycardie - tachyritmie - bradyritmie
- Gestuwde jugulaire venen (50%)
- Malleolaire oedemen (30%)

Differentiatie

Acuut longoedeem vs. bronchiaal astma


Antecedenten

Medicatie

Klinisch onderzoek (??)

+	accessoire AH-spiers	++
++	cyanose	+
+++	zweten	+
+++	crepitaties	+
rozig schuim	expectoraties	(purulent)

Cave : wheezing



Acuut longoedeem

Niet-cardiaal vs. cardiaal

- "High altitude" longoedeem
- Neurogeen longoedeem
- Narcotica overdosage
- Acute respiratory distress syndrome (ARDS)
(infecties, toxisch, shock, pancreatitis,...)
- Lymfangitis carcinomatosa
- Evacuerende pleurapunctie
- ...

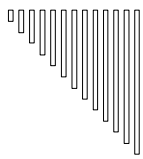
Oorzaak

Onderliggend hartlijden

- Myocardfalen
 - ischemisch
 - myocarditis
 - cardiomyopathie
- Kleplijden
- Congenitale letsels
- ...

Precipiterende factoren

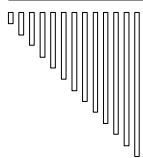
- Non-compliance
- Ritmestoornissen, pacemaker dysfunctie
- Longembolie
- Infectie (vnl. pulmonair)
- Metabole noden ↗ (inspanning, klimaat)
- Hypertensie opstoot
- Concomittante therapie
(β -blocker, corticoïden, NSAID, verapamil, ...)
- Volumebelasting (alcohol, iatrogeen)
- High output condities
- ...



Technische investigaties (1)

1. E.K.G. : obligaats

- ischemie ?? → R/ nitraten
- infarct ?? → R/ aspirine, thrombolyse
PTCA, ...
- tachyritmie ?? → R/ anti-ritmica,
DC shock,
overdrive pacing
- bradyritmie ?? → R/ pacing (AV sequentieel)
glucagon, calcium
- peri-myocarditis ??
- hypertrofie ??



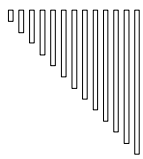
Technische investigaties (2)

2. RX-Thorax (zittend) : obligaats

- cardiomegalie (lage sensitiviteit)
cave : tamponade
- interstitieel en/of alveolair oedeem
- indirecte aanwijzingen voor cardiale
pathologie (aneurysma, pericardcalcificaties, ...)
- niet-cardiale pathologie
(pneumonie, longinfarct, pneumothorax, ...)

3. Echocardiografie : preferentieel

- ejectionfractie ??
- regionale myocardkinetiek ??
- pericardvocht ??
- kleplijden ??
- congenitale afwijkingen (VSD, HOCM,...) ??



Technische investigaties (3)

4. LABO : obligaats, tenzij [...]

→ bloedgassen :

- hypoxie : 40 - 60 mm Hg
- O₂ desaturatie : 70 - 90 %
- [• lactaat ↗ →] metabole acidose (95 %)
- CO₂ ↗ → respiratoire acidose (25 %)

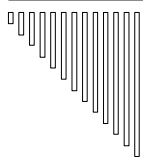
→ hartenzymen

→ hematocriet [drug dosage]
inflammatoire parameters [schildklier testen]
electrolyten [bacteriologie]
nier- en leverfunctie [d-dimeren]
→ [BNP]

5. SWAN-GANZ CATHETERISATIE : uitzonderlijk

→ diagnostisch (VSD, mitraliskleplijden, ...)

→ therapeutisch



Therapie (1)

1. O₂ (12-15 L/min) via masker met zak

2. Zittende houding

3. Diuretica

Posologie :

- Lasix® (20 mg): 1-3 ampoules over 2 min (i.v.)

- Burinex® (0,5 mg): 0,5-1 ampoule over 2 min (i.v.)

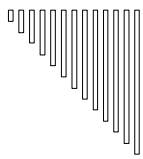
Werkingsmechanisme :

(- Venodilatatie → cave: vasoconstrictie)

- Diurese ↗ na 5 min met piek na 30 min en
duur van 2 uur

(cave: electrolytenstoornis en dehydratatie)

(- Afterload reductie)

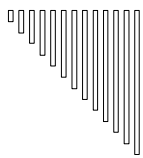


Therapie (2)

4. Nitraten (afterload ↙ , preload ↙)

Posologie

- Nitroglycerine (= trinitrine) : 0,4 - 1 mg
 - Nitrolingual® (0,4 mg) : sublinguale spray
- Isosorbide-dinitraat : 2,5 - 5 mg
 - Cedocard® - Isordil® (5 mg) : sublinguaal (evt. gevolgd door continue i.v. of transdermale toediening)



Werkingsmechanisme (na 2 - 5 min werkzaam)

- Venodilatatie
- Coronaire vasodilator
- Afterload reductie (cave : hypotensie en coronaire hypoperfusie)
- (• Pulmonaire vasodilator)

THE LANCET

Volume 351, Number 9100

ARTICLES

Articles

Randomised trial of high-dose isosorbide dinitrate plus low-dose furosemide versus high-dose furosemide plus low-dose isosorbide dinitrate in severe pulmonary oedema

Gad Cotter, Elnat Metzkor, Edo Kaluski, Zwi Faigenberg, Rami Miller, Avi Simovitz, Ori Shaham, Doron Marghitay, Maya Koren, Alex Blatt, Yaron Moshkovitz, Ronit Zaidenstein, Ahuva Golik

Summary

Background Nitrates and furosemide, commonly administered in the treatment of pulmonary oedema, have not been compared in a prospective clinical trial. We compared the efficacy and safety of these drugs in a randomised trial of patients with severe pulmonary oedema and oxygen saturation below 90%.

Methods Patients presenting to mobile emergency units with signs of congestive heart failure were treated with oxygen 10 L/min, intravenous furosemide 40 mg, and morphine 3 mg bolus. 110 patients were randomly assigned either to group A, who received isosorbide dinitrate (3 mg bolus administered intravenously every 5 min; n=56) or to group B, who received furosemide (80 mg bolus administered intravenously every 15 min, as well as isosorbide dinitrate 1 mg/h, increased every 10 min by 1 mg/h; n=54). Six patients were withdrawn on the basis of chest radiography results. Treatment was continued until oxygen saturation was above 96% or mean arterial blood pressure had decreased by 30% or to below 90 mm Hg. The main endpoints were death, need for mechanical ventilation, and myocardial infarction. The analyses were by intention to treat.

Findings Mechanical ventilation was required in seven (13%) of 52 group-A patients and 21 (40%) of 52 group-B patients (p=0.0041). Myocardial infarction occurred in nine (17%) and 19 (37%) patients, respectively (p=0.047). One patient in group A and three in group B died (p=0.61). One or more of these endpoints occurred in 13 (25%) and 24 (46%) patients, respectively (p=0.041).

Interpretation High-dose isosorbide dinitrate, given as repeated intravenous boluses after low-dose intravenous furosemide, is safe and effective in controlling severe pulmonary oedema. This treatment regimen is more effective than high-dose furosemide with low-dose isosorbide nitrate in terms of need for mechanical ventilation and frequency of myocardial infarction.

Lancet 1998; 351: 389-93
See Commentary page 382

Therapie (3)

5. Morfinesulfaat (ampoules: 10 mg / 1 ml)

Indicatie

Minimaal, tenzij pijnproblematiek

Posologie

- (i.v.) : 3 - 5 mg over 3 min. eventueel
 - tot 3 maal te herhalen met 15 min interval (cave : respiratoire depressie
→ Narcan® beschikbaar hebben)
- (s.c. - i.m.) 8-15 mg, evt. te herhalen elke 3 à 4u

Werkingsmechanisme

- centraal sympatolytisch effect
→ preload ↙ (+ afterload ↙)
- angst ↙



Therapie (4)

6. Digitalis

- wsch. zinvol bij (de novo) VKF met snel ventriculair antwoord
- evt. zinvol bij sinusritme, systolische dysfunctie en geen onderhoudsbehandeling met digitalis

Posologie voor digoxine (1 amp : 500 µg)

Ladingsdosis (i.v.): 500-1000 µg over 5 à 10 min

Werkingsmechanisme

- Ventriculaire respons bij VKF (AV geleiding) ✓
- Positief inotroop (inhibitie van Na⁺-K⁺ ATP-ase)



Therapie (5)

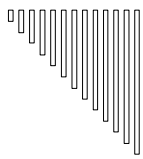
7. Captopril (ACE-inhibitie)

Beperkte gunstige klinische ervaring met Captopril (12,5 of 25 mg, s.l.), vnl. in combinatie met nitraten

8. Bronchodilatoren : te overwegen bij "cardiaal asthma"

9. "Non-invasive positive ventilation" / Mechanische ventilatie

10. Vasopressoren



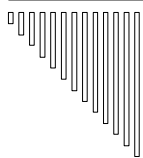
Therapie (6)

11. Hemofiltratie : bij nierinsufficiëntie

12. Therapie/correctie van precipiterende factoren :

- infectie → antibiotica
- longembool → anticoagulantia
- intoxicatie → antidoten
- tachy-aritmie → anti-aritmica, DC shock, ...
- brady-aritmie → pacing

...



Prognose

Mortaliteit

Tijdens opname : 17%

Na 1 jaar : 40%

Prognostisch gunstig

Systolische hypertensie (> 160 mm Hg)

bij opname



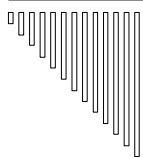
Acuut rechter hartfalen

Etiologie

- (1. Exacerbatie van chronisch rechter hartfalen)
- 2. Rechter ventrikelfarct
- 3. Massief longembol

Symptomen

- Draaiduizeligheid, syncope (bij inspanning)
 - Abdominale klachten: pijn in epigastrium / rechter hypochondrium, anorexia, nausea, braken
 - Low output → shock
-



Cardiogene shock

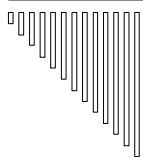
- (1. Anamnese)
 - 2. Klinisch beeld
 - (3. Etiologie)
 - 4. Differentiaal diagnose
 - (5. Technische investigaties)
 - 6. Therapie
-



Differentiaal diagnose (1)

Via :

- (hetero-)anamnese
 - klinisch onderzoek
 - E.K.G.
 - Echocardiografie
 - Swan-Ganz monitoring
 - . . .
-



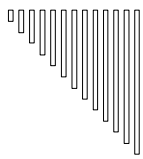
Differentiaal diagnose (2)

Hypovolemische shock :

- Bloedverlies
- Brandwonden
- Dehydratatie
- Diarree

Distributieve shock / vasomotorische dysfunctie :

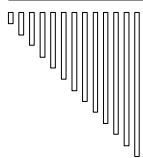
- Sepsis
 - Anafylaxis
 - Spinale shock
 - Intoxicatie met vasodilatoren
-



Differentiaal diagnose (3)

Obstructieve shock (extra-cardiaal)

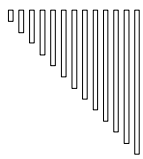
- Tamponade
 - Longembool
 - Spanningspneumothorax
-



Differentiaal diagnose (4)

Cardiogene shock

- Eindstadium van chronisch hartfalen
 - Ventriculopenische shock (massief LV-infarct)
 - Rechter ventrikelfarct
 - Complicaties van AMI (VSD, MI)
 - Klepinsufficiëntie
 - Ritmestoornissen
 - Intracardiale obstructie (klepstenose, tumorale massa, luchttembool)
 - Intoxicatie met negatief inotrope farmaca
 - Posttraumatisch
-

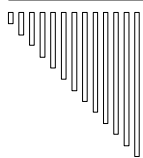


Therapie van cardiogene shock (1)

A. Etiologie-gerichte therapie

- AMI → primaire PTCA, thrombolytica
- acut kleplijden → cardiochirurgie
- tachy-aritmie → DC shock
- brady-aritmie → pacing
- intoxicatie → antidoten


...



Therapie van cardiogene shock (2)

B. Algemene therapieregel : VIP

1. Ventilatie
 - intubatie : $pO_2 < 60$ mm Hg en/of $pCO_2 > 60$ mm Hg
 - sedatie
 - neuromusculaire blockade
2. Infuus
 - ~ vullingsdrukken (PCW 15-18 mm Hg)
3. Pompfunctie ondersteunen
 - ~ cardiac index (CI $> 2,2$ L/min/m²)



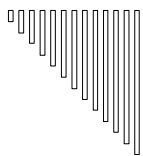
Acuut myocardinfarct en cardiogene shock

Differentiaaldiagnose

1. Ventriculopenische shock
2. VSD
3. Mitralisklepinsufficiëntie
4. Rechter ventrikelfarct

Hoe differentiëren ?

1. Klinisch onderzoek
 2. E.K.G.
 3. Echocardiografie
-



Specifieke ziektebeelden (1)

1. Ventriculopenische shock

- Zie hoger
 - desocclusie :
 - thrombolysie
 - desocclusie PTCA
 - CABG
 - IABP
-

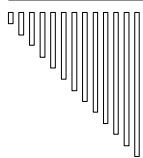


Specifieke ziektebeelden (2)

2. Ventricular septal defect

- Clinical findings :
 - Incidence 1-2% of all infarctions
 - Occurs 3-5 days after infarction
 - Equally frequent in anterior and infero-posterior infarctions
 - New onset systolic murmur loud and holosystolic, widespread propagation
 - Palpable precordial thrill (50%)

 - Diagnostic techniques : echocardiography
 - Discontinuity of septum
-



Specifieke ziektebeelden (3)

3. Mitral insufficiency

- Clinical findings :
 - Incidence 1% of all infarctions
 - Occurs 3-5 days after infarction
 - In 90% with inferoposterior infarctions
 - New onset systolic murmur usually loud and holosystolic, may vary in intensity/propagation or be absent
 - Palpable thrill very rare (2%)

 - Diagnostic techniques :
 - 2-D echocardiography: flail or prolapsing leaflet
 - Doppler flow: systolic regurgitant jet into LA
-



Specifieke ziektebeelden (4)

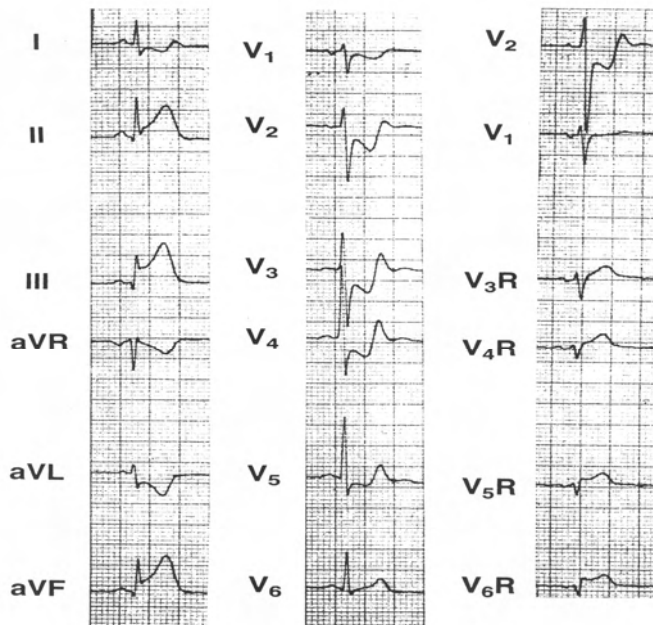
4. Rechter ventrikelfarct

□ Diagnose :

- EKG : inferior- (posterior-) infarct + ST-optrekkingen in V_4R
- Echocardiografie
- Swan-Ganz monitoring :
 - lage cardiac output
 - lage PCW
 - hoge RA-druk (RA / PCW > 0.86)

□ Therapie :

- Volume expansie (cave: morfine, nitraten, diuretica)
- Dobutamine (min. $P_{art.P.}$ ↗)
- (indien ook LV dysfunctie) afterload ↘: nitroprusside, IABP



Acute inferoposterior wall myocardial infarction and right ventricular infarction. Note the elevated ST segment in lead V_4R , indicating an occlusion in the proximal right coronary artery and right ventricular involvement.