

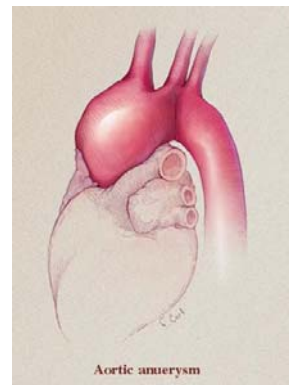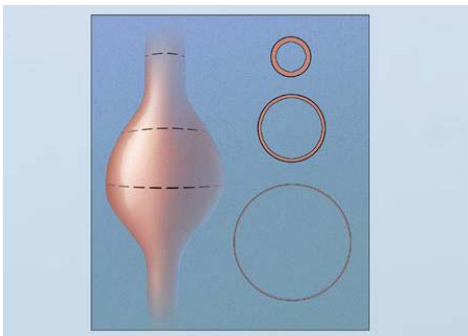
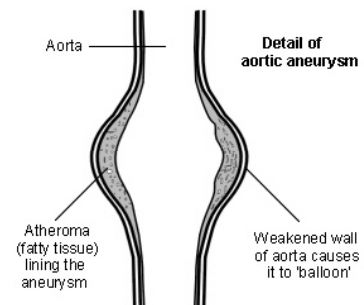
# AORTA-CHIRURGIE

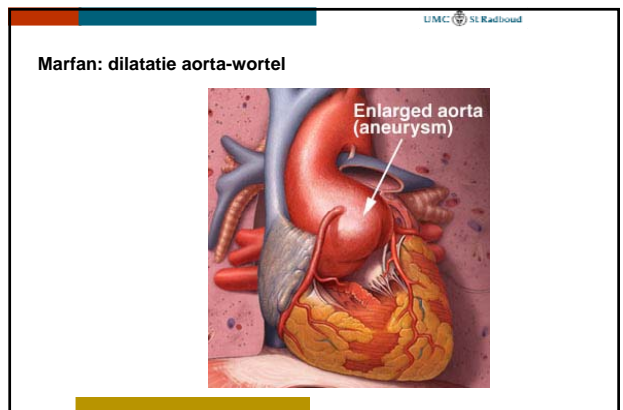
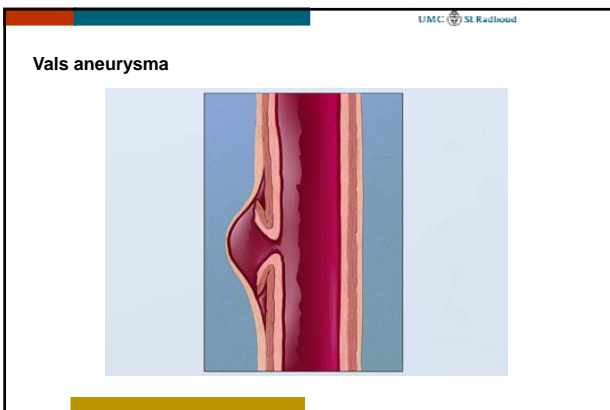
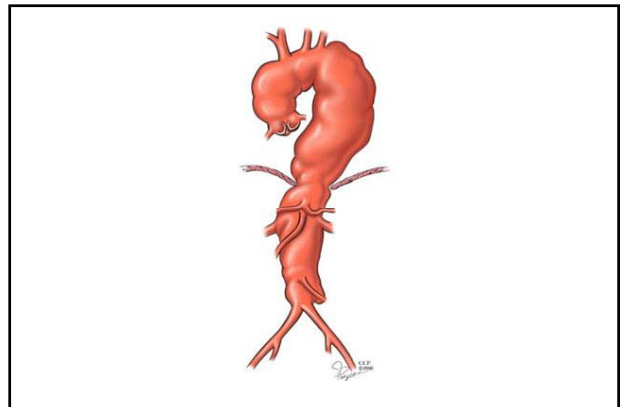
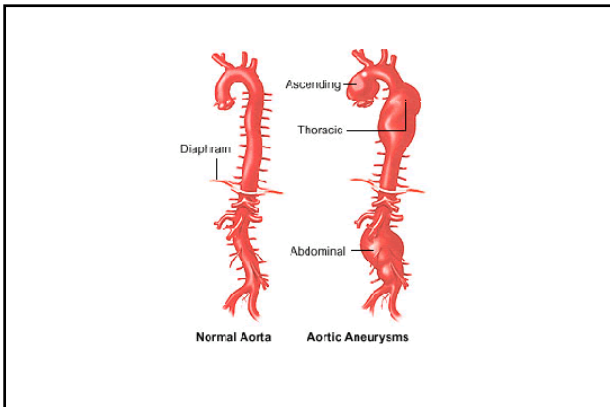
H.van Wetten  
 Cardio-thoracale chirurgie

# AORTA-ANEURYSMA

## Aneurysma

- Verwijding van alle lagen : intima, media en adventitia
- Toename van diameter geeft toename van wandspanning
  - Wet van Laplace :  $T = P \times r$
- Oorzaken
  - Bindweefselafwijkingen: Marfan e.d., medianecrose
  - Atherosclerose
  - Post-stenotisch
  - Na dissectie
- Risico: dissectie, ruptuur





UMC St Radboud

**Aneurysma : indicaties interventie**

- Aorta ascendens : > 5 cm diameter (Marfan > 4.5 cm)
- (snelle) progressie diameter
- "scheurfamilie": in familie personen met dissecties/acute dood

UMC St Radboud

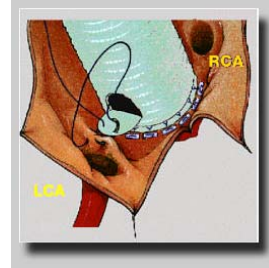
**Aneurysma : interventie**

- Stent
  - Aorta descendens/abdominaal
- Operatie
  - Verkleinen diameter (reven)
  - Vervanging:
    - Supracoronaire ascendensvervanging
    - Klepsparende wortelvervanging : Yacoub, David
    - Klepvervanging : Bentall
  - Boog : reïmplantatie halsvaten

Klephoudende graft: Bentall-procedure



Bentall-procedure



Bentall-procedure

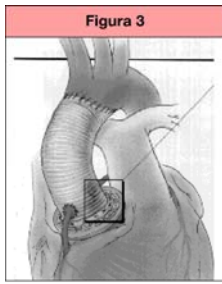
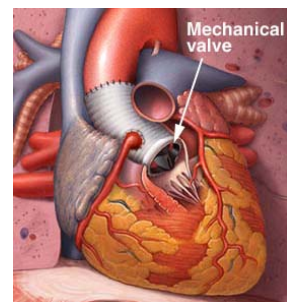
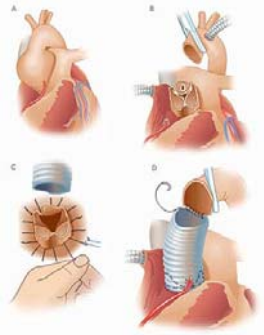


Figura 3. Operació de Bentall-De Bono amb la modificació de la implantació de les coronàries amb tècnica de botó.

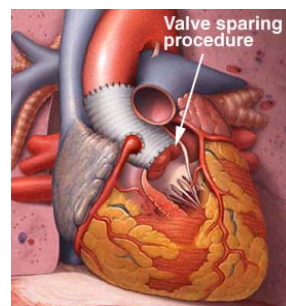
Bentall-procedure

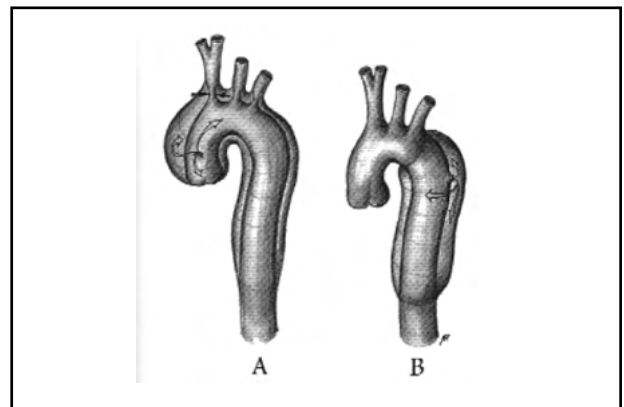
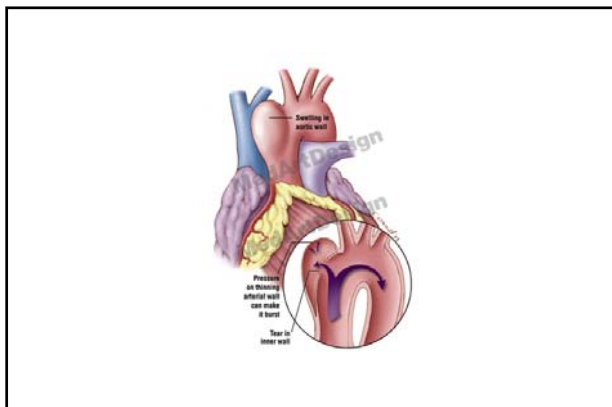
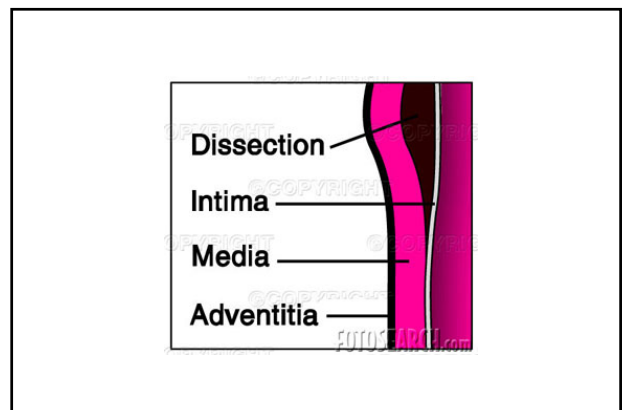
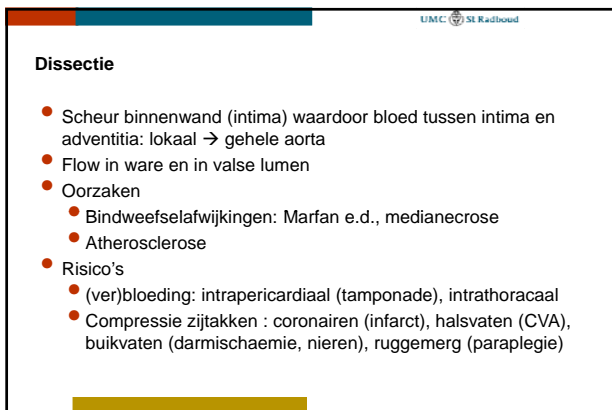
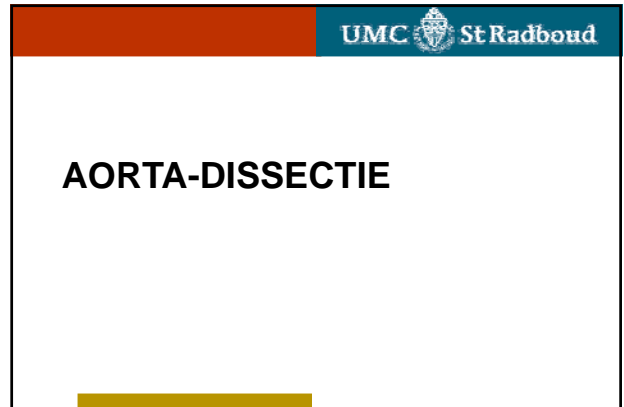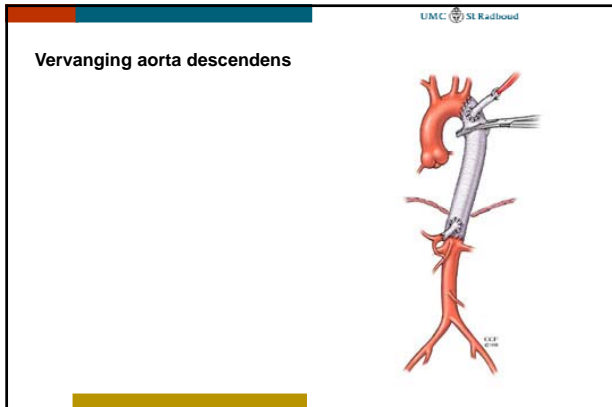


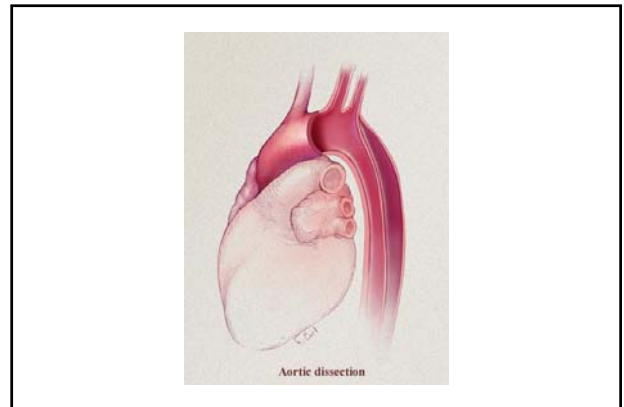
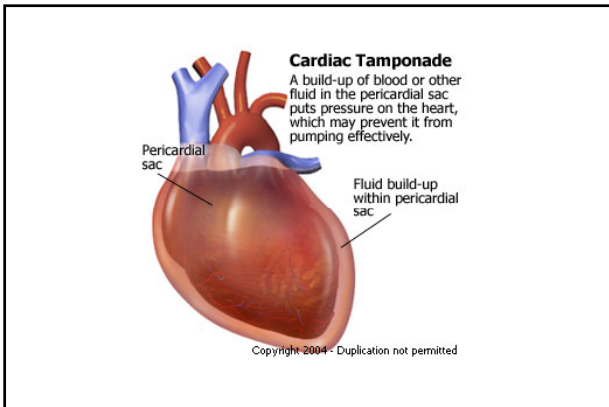
Klepparende aortawortel-  
vervanging (David)



Valve sparing  
procedure







UMC St Radboud

**Dissectie : indicaties interventie**

- Aorta ascendens : i.p. spoedindicatie operatie ("Golden Hour")
- Aorta-boog : idem
- Aorta descendens :
  - i.p. conservatief : bedrust, bloeddrukverlaging (B-blokker)
  - Interventie :
    - Blijvende klachten
    - Uitvalsverschijnselen: nieren, darmen, benen

UMC St Radboud

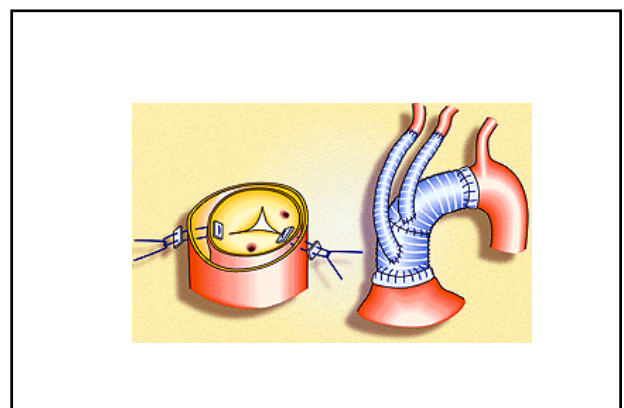
**Dissectie : interventie**

- Stent
  - Aorta desendens/abdominaal
- Operatie
  - Verkleinen diameter (reven)
  - Vervanging: reimplantatie coronairen
    - Klepsparend : Yacoub, David
    - Klepvervanging : Bentall
  - Boog : reimplantatie halsvaten

UMC St Radboud

**Dissectie : interventie**

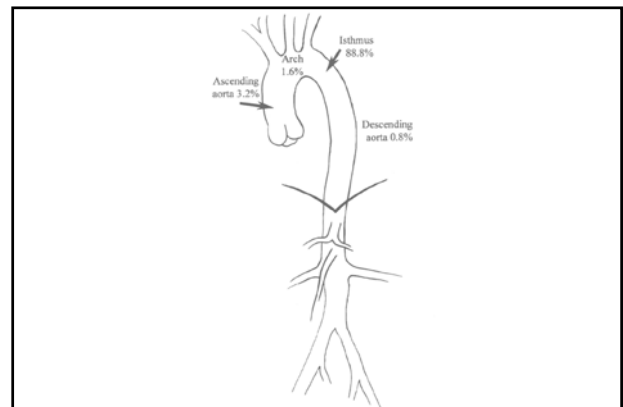
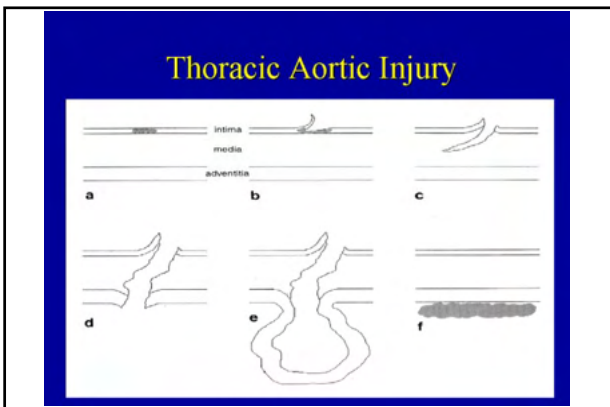
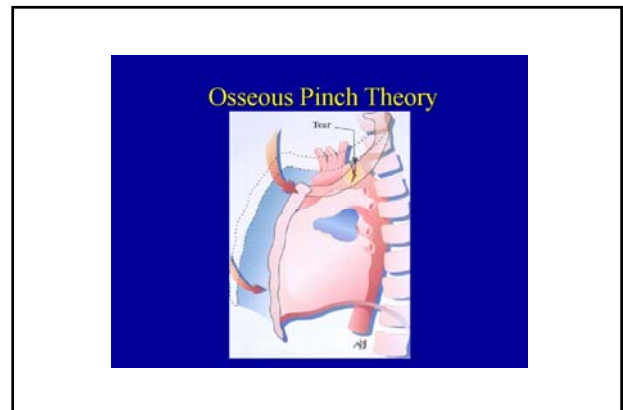
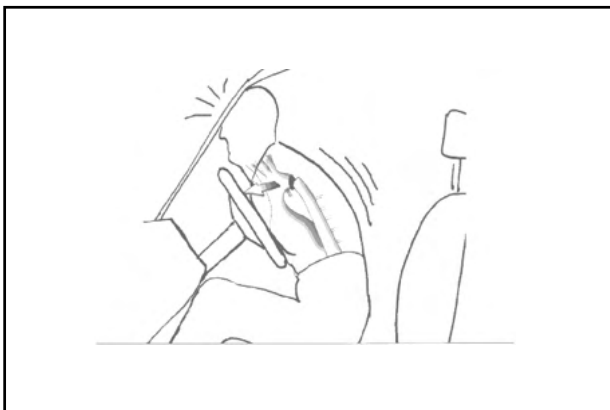- Stent
  - Aorta desendens/abdominaal
- Operatie
  - Vervanging:
    - Supracoronaire ascendensvervanging
    - Klepsparende wortelvervanging : Yacoub, David
    - Klepvervanging : Bentall
  - Boog : reimplantatie halsvaten

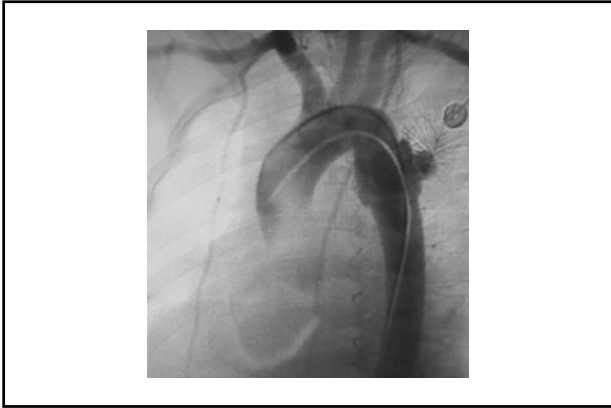


# AORTA-RUPTUUR

## Ruptuur

- Scheur binnenwand circulair, adventitia intact
  - Voorkeur: tpv ligamentum Botalli, ascendens, diafragma
- Oorzaken
  - Deceleratie-trauma : auto-gordel/stuur
- Risico's
  - (ver)bloeding: intrathoracaal






UMC St Radboud

**Ruptuur : interventie**

- Stent
- Ascendens: operatie zoals bij dissectie



UMC St Radboud

A solid yellow horizontal bar at the bottom of the slide.