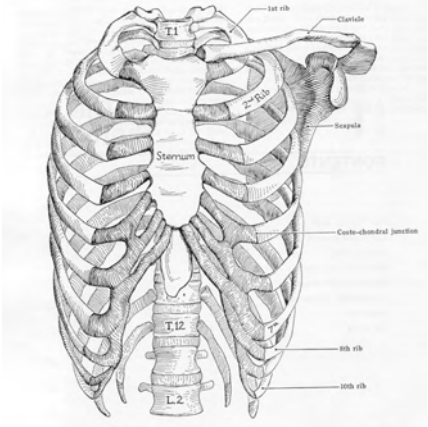

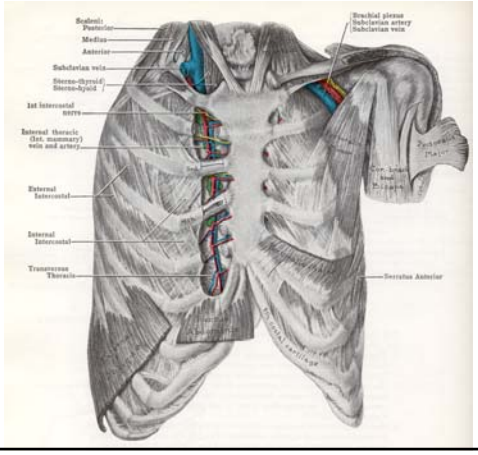

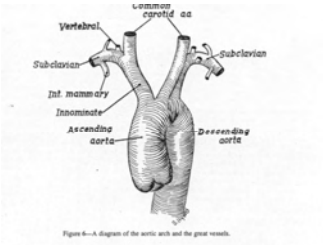

Figure 6—A diagram of the aortic arch and the great vessels.

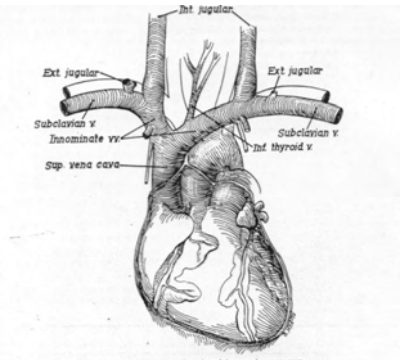

Figure 16—A diagram of the tributaries of the superior vena cava.

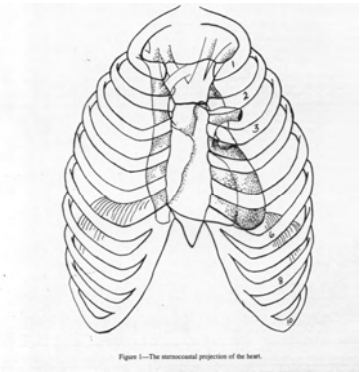

Figure 1—The sternocostal projection of the heart.

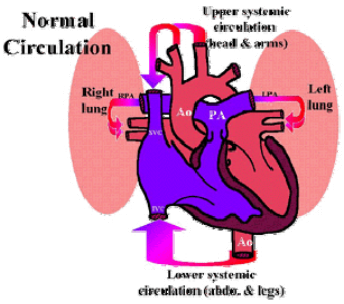

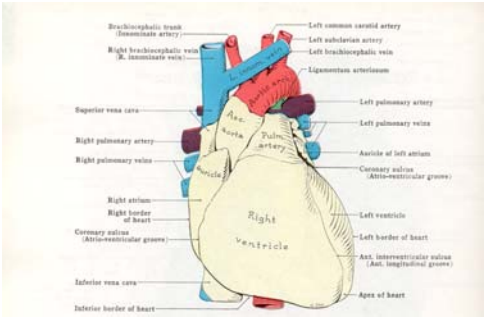
Right
Ventricle

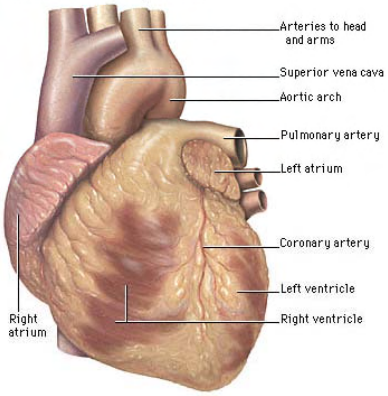
Exterior structures of the heart
Arteries to head and arms
Superior vena cava
Aortic arch
Pulmonary artery
Left atrium
Coronary artery
Left ventricle
Right ventricle
Right atrium

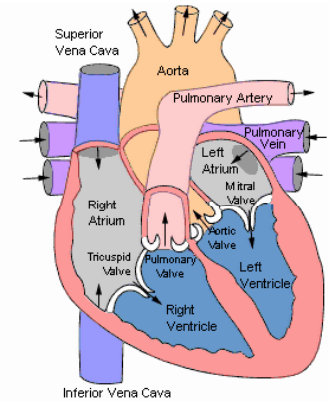
Superior Vena Cava
Aorta
Pulmonary Artery
Pulmonary Vein
Left Atrium
Mitral Valve
Right Atrium
Aortic Valve
Tricuspid Valve
Pulmonary Valve
Left Ventricle
Right Ventricle
Inferior Vena Cava

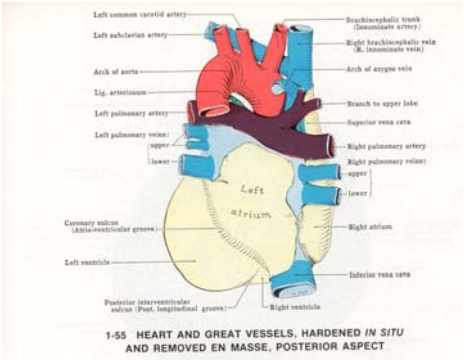
Left atrium
1-55 HEART AND GREAT VESSELS, HARDENED IN SITU AND REMOVED EN MASSE, POSTERIOR ASPECT

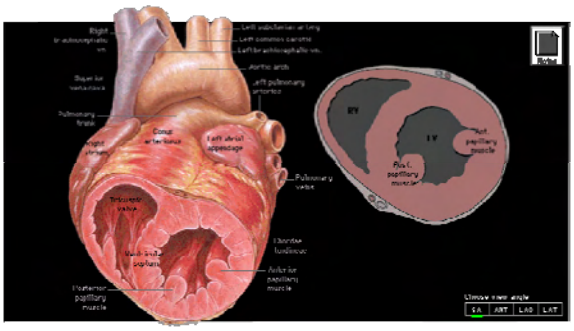

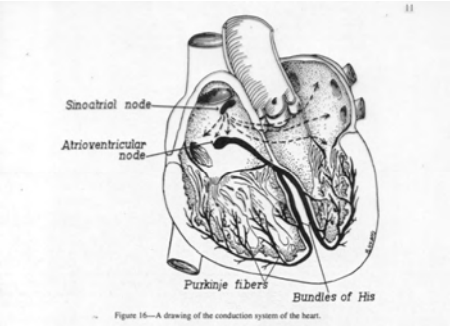
Sinoatrial node
Atrioventricular node
Purkinje fibers
Bundles of His
Figure 16—A drawing of the conduction system of the heart.

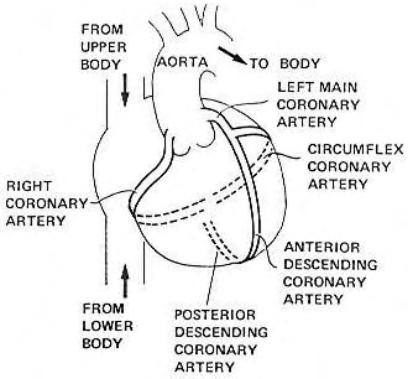

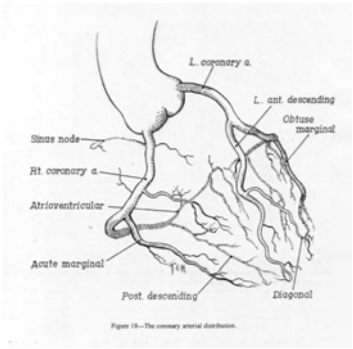

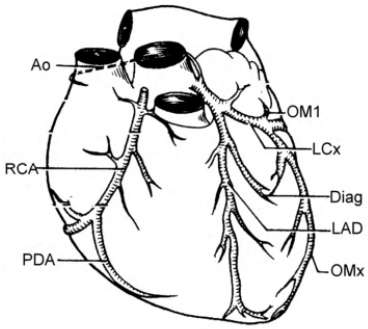

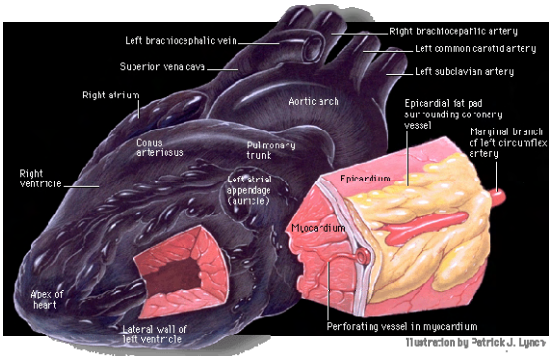

Coronary arteries are the network of blood vessels that supply the heart. In this photograph, the left coronary artery has been injected with a red dye, and the right coronary artery with white.

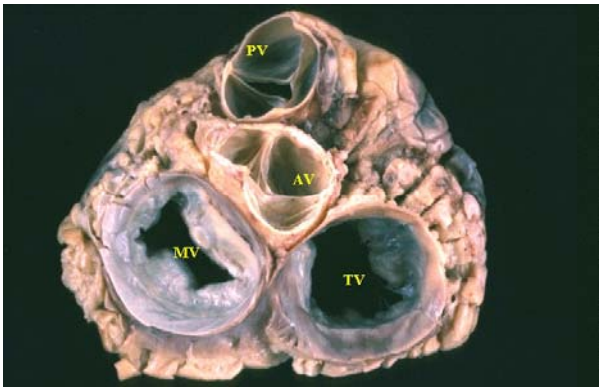

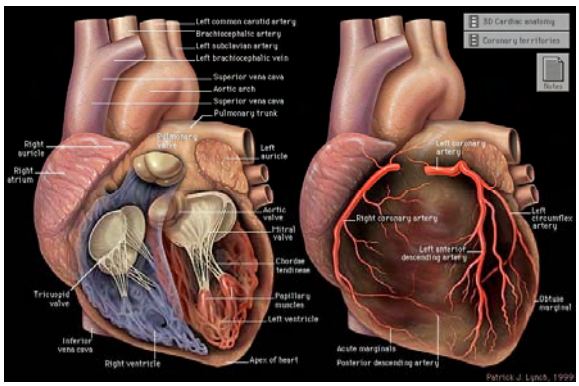

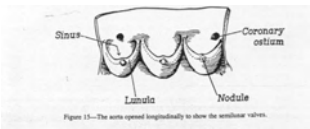

Figure 15—The aorta opened longitudinally to show the semilunar valves.

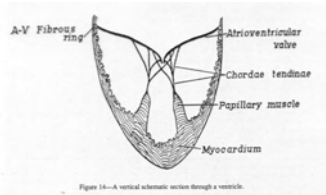
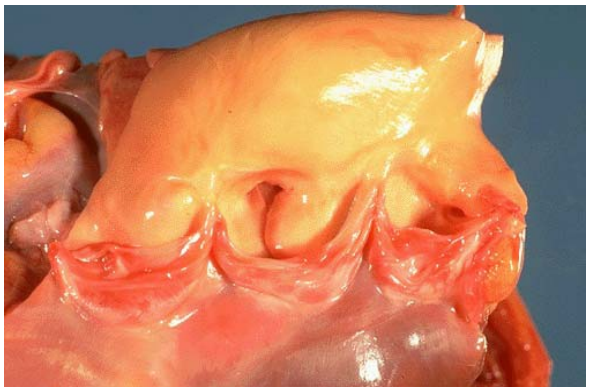
Figure 14—A vertical schematic section through a ventricle.